

“Please Tell the World What They Have Done to Us”

The Chut Pyin Massacre:
Forensic Evidence of Violence against the Rohingya in Myanmar

July 2018





Contents

- 3 Executive Summary
- 4 Introduction
- 5 Methodology
- 8 Map of Myanmar
- 9 Background of the Rohingya in Myanmar
- 9 Increasing Waves of Violence (2012-2017)
- 12 Rising Tensions in the Village of Chut Pyin
- 13 The Chut Pyin Massacre
- 14 The Chut Pyin Massacre Infographic
- 15 Forensic Analysis
- 21 Survivor Statistics Table
- 22 Human Rights Analysis
- 30 Conclusion
- 31 Recommendations
- 33 Case Profiles Map
- 34 Case Profiles
- 62 Endnotes

Cover: PHR's Homer Venters, MD examines an x-ray of 13-year-old Ayaesha Siddiqa (Profile 13), who was shot in the hip as she fled Chut Pyin. The injury left shrapnel in her body and continues to cause her pain when she walks. Ayaesha's father, brother, sister-in-law, and nephew were all killed in the Chut Pyin massacre.

Photo: Salahuddin Ahmed for Physicians for Human Rights

Acknowledgments

This report was written by Tamaryn Nelson, MPA, acting director of research and investigations for Physicians for Human Rights (PHR).

The report was reviewed, edited, and prepared for publication by Claudia Rader, MS, content and marketing manager.

Research design and implementation was conducted by the following PHR Medical Experts: Rohini Haar, MD, MPH, research fellow at the Human Rights Center, University of California, Berkeley and clinical faculty in the Department of Emergency Medicine, Highland General Hospital and Kaiser Medical Center, Oakland, California; Parveen Parmar, MD, MPH, chief of the Division of International Emergency Medicine and associate professor of clinical emergency medicine at the University of Southern California's Keck School of Medicine; Rupa Patel, MD, MPH, DTM&H, assistant professor in the Division of Infectious Diseases and director of the HIV Pre-Exposure Prophylaxis (PrEP) Program at Washington University in St. Louis; Homer Venters, MD, MS, PHR director of programs; and Karen Wang, MD, MHS, instructor of medicine at Yale University School of Medicine. They worked with a team of local fixers and interpreters who remain anonymous for safety reasons. PHR's Ethics Review Board approved the research design for this study.

Leadership and staff of PHR contributed to the writing and editing of this report, including DeDe Dunevant, director of communications; Carolyn Greco, JD, former senior U.S. policy associate; Vincent Iacopino, MD, PhD, senior medical advisor; Donna McKay, executive director; and Susannah Sirkin, MEd, director of international policy and partnerships. PHR interns Angelica Rossi-Hawkins and Iliana Ruiz also contributed to this report. External review was provided by a range of experts in the fields of medicine, law, and human rights in Myanmar.

PHR would also like to acknowledge the support of MedGlobal in conducting forensic examinations and is grateful to all local partners who provided support, including Rohingya partner Htike Htike, who helped coordinate field activities. PHR is especially indebted to the Rohingya people who were willing to share their experiences for this report.

Executive Summary

On August 27, 2017, Myanmar security forces and Rakhine Buddhist civilians attacked the village of Chut Pyin in northern Rakhine state, massacring its Rohingya Muslim residents and burning their homes to the ground.

The attackers perpetrated a vast array of human rights violations on the Rohingya villagers, including killings, disappearances, beatings, stabbings, rape, and forcible displacement. It is estimated that some 400 Chut Pyin villagers, including 99 children, were killed that day or are missing – including a group of 50 men who were taken away and never seen again.

Similar attacks have killed thousands of Rohingya and pushed at least 720,000 refugees into neighboring Bangladesh since August 2017. As part of a broad effort to secure forensic evidence of atrocities against the Rohingya, Physicians for Human Rights (PHR) interviewed and conducted forensic examinations of 22 survivors – men, women, and children – of the Chut Pyin massacre. The injuries PHR doctors documented, including gunshot wounds, blunt-force trauma, lacerations, and more, serve as clear medical evidence to corroborate the survivors' accounts of shooting attacks, beatings, stabbings, and other forms of violence which occurred on that day.

Based on the forensic examinations and the consistent and detailed testimony of these Chut Pyin survivors, as well as corroborating information from additional credible sources, PHR believes that the savagery inflicted on the people of Chut Pyin is a typical example of the widespread and systematic campaign that Myanmar authorities have waged against the Rohingya people – acts that should be investigated as crimes against humanity.



A Rohingya refugee carries his injured relative after crossing the river from Myanmar into Bangladesh in October 2017.

Photo: Munir Uz Zaman/AFP/Getty Images

Introduction

For centuries, Muslim Rohingya people have lived in Rakhine state on the western coast of Myanmar, a predominantly Buddhist country. Since the Myanmar military junta stripped the Rohingya of citizenship in 1982, the Rohingya have been stateless and subjected to decades of human rights violations, including denial of the right to health and education, limited political participation, restrictions on freedom of movement, forced displacement, arbitrary detentions and killings, forced labor, and trafficking, among other abuses.¹

Following alleged attacks on Myanmar security forces by the insurgent Arkan Rohingya Salvation Army in October 2016, and again in August 2017, the Myanmar military unleashed attacks on Rohingya communities² which have driven more than 720,000 Rohingya into neighboring Bangladesh from August 2017 to June 2018.³

Physicians for Human Rights (PHR) has conducted three visits to Bangladesh since October 2017 to interview and carry out forensic medical examinations of Rohingya survivors of these attacks. This report focuses on the events that occurred in the village of Chut Pyin as an example of what happened in dozens of villages in Rakhine state: the Rohingya villagers faced a host of human rights violations, including killings; detentions and disappearances; physical assault involving beatings, stabbings, and mutilations; rape and other forms of sexual violence; and forced displacement in the form of looting and burning of homes.

Several survivors interviewed by PHR, many of them women and children, faced multiple violations. Most survivors did not have access to adequate emergency medical care. They then endured a 150-kilometer (roughly 100-mile) journey, often walking for up to 10-12 days, to seek refuge in the Cox's Bazar area of Bangladesh.

To date, Myanmar authorities have failed to conduct impartial and independent investigations into these events and have not fully cooperated with others seeking to do so.⁴ A United Nations fact-finding mission on Myanmar, created in 2017, has a mandate to collect evidence that may be used in potential future prosecutions, but has been barred from entering the country. Myanmar authorities also denied the UN-appointed Myanmar human rights expert, Yanghee Lee, any further access or cooperation following the publication of her findings.⁵

In November 2017, an internal report by the Myanmar military acquitted itself of any wrongdoing⁶ and several human rights organizations have been calling on the UN Security Council to refer Myanmar to the International Criminal Court (ICC) to investigate allegations of crimes against humanity.⁷ In June 2018, the ICC itself sent a request to Myanmar asking to exercise jurisdiction over the alleged crime of deportation, while one of the ICC prosecutors asked the Court to consider whether prosecution could take place through Bangladesh, given the influx of 720,00 Rohingya people into the country.⁸

At the same time, the Myanmar government announced the creation of an “independent commission of inquiry”⁹ to investigate further allegations of human rights abuses in Rakhine state. Given Myanmar's limited past efforts on justice and accountability, there are reasonable grounds for concern about whether these investigations will be carried out in an objective and impartial manner. For example, in April 2018 the Myanmar military announced that an internal investigation had led to the sentencing of seven soldiers for the killing of 10 Rohingya men whose bodies were found in a mass grave at Inn Din village in northern Rakhine state – though the reporters who broke the story

were arrested and detained.¹⁰ Moreover, the Myanmar military continues to deny responsibility for incidents in the dozens of other Rohingya villages.

PHR is publishing this report based on testimonies and forensic evaluations of Chut Pyin individual cases to contribute to documentation and investigation efforts, so that those who perpetrated these crimes can be held accountable and survivors may be given redress. This report draws exclusively on testimonies that demonstrated a high degree of consistency between described events and forensic examination findings, and with overall information reported by other credible sources.

Methodology

Field Investigations

Physicians for Human Rights (PHR) has conducted three field investigations in Rohingya refugee camps (Balukhali, Jamtoli, Kutupalong, and Thangkali) near Cox's Bazar, Bangladesh. During an initial visit in October 2017, the PHR clinical team established contact with local health providers working in camps in the area and assessed the need to collect scientific and medical evidence in the form of forensic evaluations. In December 2017, the PHR clinical team returned to conduct interviews and forensic examinations of survivors from 25 villages across Rakhine state, from where most Rohingyas have fled since the August 2017 attacks. In consultation with partner organizations, PHR then selected Chut Pyin as a village for a set of in-depth evaluations. To complete this focused work, PHR carried out a third field investigation to Bangladesh in February 2018.

PHR Medical Expert Karen Wang, MD, MHS interviewing Rohingya survivors in Thangkali refugee camp in Bangladesh.

Photo: Salahuddin Ahmed for Physicians for Human Rights



Terminology

In this report, the term “Rakhine Buddhist” refers to Buddhist people of Rakhine ethnicity, and “Rohingya” refers to Muslim people of Rohingya ethnicity. “Myanmar security forces” encompasses the military and Border Guard Police (BGP) officers; the term “Rakhine Buddhist civilians” in the context of the Chut Pyin attack refers to armed Rakhine civilians who seem to have acted in concert with, or at least with acquiescence from, Myanmar authorities during attacks on the Rohingya.¹¹

Key Informants

To accumulate a critical mass of cases, PHR's clinical team used chain sampling, whereby key non-governmental organizations and medical centers in the field identified survivors; these, in turn, referred the team to additional interviewees. All survivors interviewed were adults or accompanied minors who self-identified as Rohingya and who were in surrounding hospitals or lived in refugee camps in the Ukhiya and Teknaf areas south of Cox's Bazar. PHR excluded anyone who arrived before August 27, 2017 and/or was unable to provide consent.

The PHR research team interviewed nearly 100 key informants, including survivors, community leaders, medical professionals, activists, lawyers, journalists, and others. Out of the 81 Rohingya survivors from approximately 25 villages in Rakhine state who were interviewed, 25 survivors were from the village of Chut Pyin: 22 of these 25 interviewees sustained physical injuries or abuses and underwent a forensic examination – 12 adults (seven women and five men) and 10 minors under the age of 18 (four girls and six boys). The additional three Chut Pyin interviewees were witnesses who did not sustain injuries and who provided background information.

This report focuses on information from these 25 Chut Pyin survivors. Additionally, PHR drew upon interviews with three other witnesses who participated in Chut Pyin meetings with Myanmar security forces prior to August 27, 2017, and soon thereafter faced similar attacks in their neighboring villages.

Consent and Ethics Approval

The PHR researchers obtained verbal and written consent from each interviewee through an interpreter, following a detailed explanation of PHR's work, the purpose of the investigation, and its voluntary nature. For reasons of safety and confidentiality, PHR replaced the names of survivors with pseudonyms and blurred their faces in the images used in this report.

PHR's Ethics Review Board provided guidance and approved this study based on regulations outlined in Title 45 CFR Part 46, which are used by academic Institutional Review Boards in the United States. All of PHR's research and investigations involving human subjects are conducted in accordance with the Declaration of Helsinki 2000, a statement of ethical principles for medical research involving human subjects, including research on identifiable human material and data.¹²

Interviews and Forensic Examinations

The findings of this report are based on two-part assessments – interviews and forensic examinations – conducted in private locations with a trained interpreter in the Rohingya language.

Each assessment began with a semi-structured interview to collect information on the survivor's demographics and their personal experiences, as well as when they first noted any disturbances in daily life in late August 2017 and how they arrived in their current location. Questions centered on the survivor's own experiences and witnessed instances of abuse.

PHR then conducted forensic examinations using a questionnaire that reflects the basic elements of the Istanbul Protocol, the international standard to assess, investigate, and report alleged instances of torture and other cruel, inhuman, and degrading treatment.¹³

This study focused on physical forensic examinations of the area of reported injuries; available diagnostic images, laboratory tests, and other medical records were also reviewed.

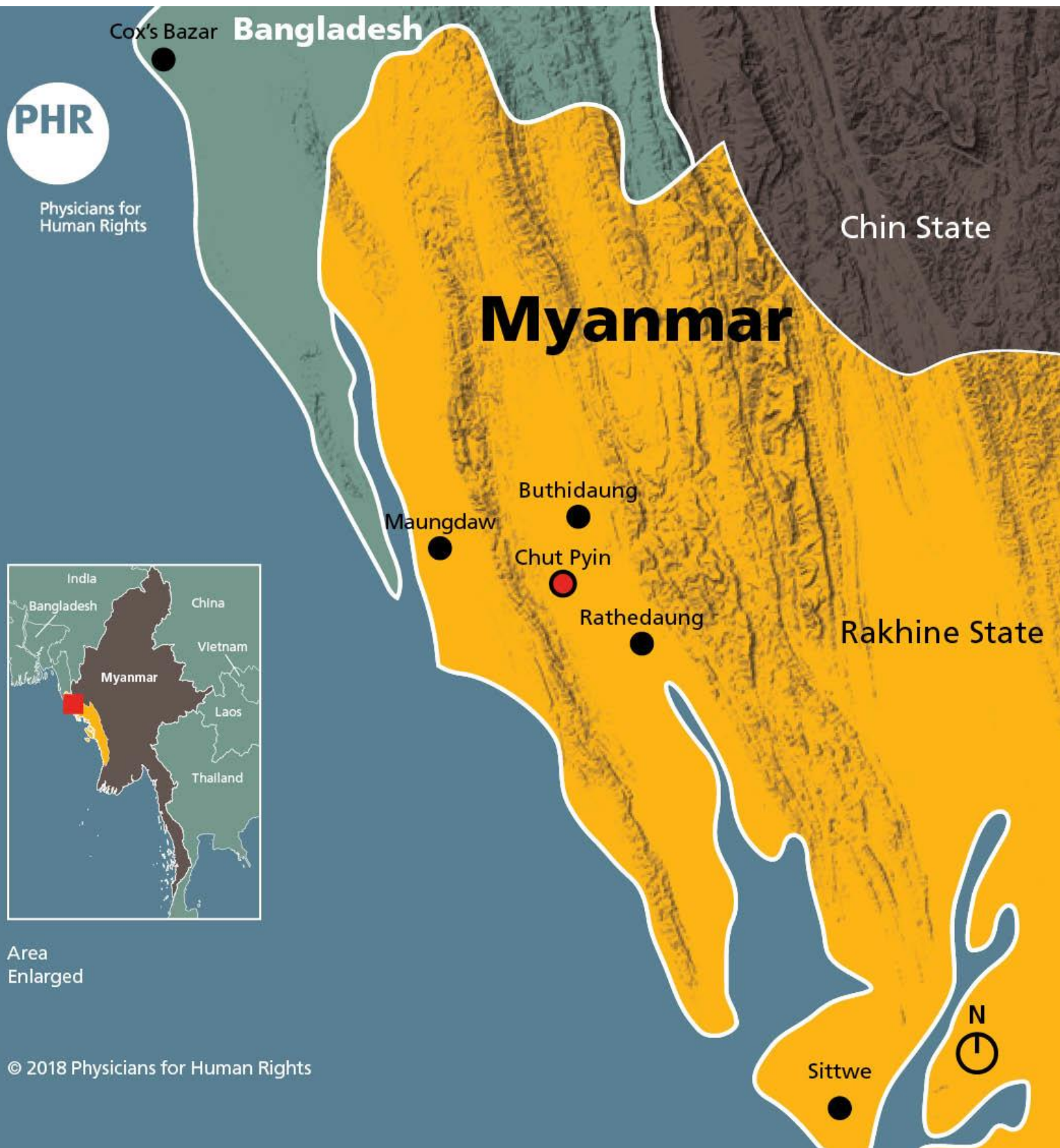PHR Clinical Team

The clinical team involved in field investigations related to Chut Pyin was composed of three PHR Medical Experts: Rupa Patel, MD, MPH, DTM&H; Homer Venters, MD, MS; and Karen Wang, MD, MHS. The PHR clinicians also worked with local translators and a fixer who assisted with logistical arrangements.

Limitations

This PHR report sheds light on how one attack unfolded and provides key forensic evidence on how it affected 25 villagers in Chut Pyin in order to substantiate efforts to bring those responsible to justice. However, it is not intended to provide a full analysis of the human rights violations faced by all Chut Pyin villagers or by the Rohingya population generally. That said, research from PHR is highly consistent with the fieldwork of other sources, demonstrating that the attack on Chut Pyin follows patterns seen in other villages and exemplifies the type of violence carried out against the Rohingya in Myanmar in August 2017.

The survivors were interviewed six months after the attack and demonstrated symptoms of trauma. This timing may have exacerbated recall bias, where one is more likely to remember events believed to relate to the experience. To this end, this report draws exclusively on testimonies that demonstrated a high degree of consistency between the interviewees' described events and the findings of their physical forensic examination, as well as consistency with overall events (dates/locations) reported by other credible sources.



Muslims comprise an estimated 4 to 10 percent of Myanmar's population, and most live in Rakhine state. The majority of Rakhine Muslims are Rohingya, an ethnic group living along the country's western border with Bangladesh and India.

Background of the Rohingya in Myanmar

Myanmar is a diverse country with many ethnic groups, languages, and religions. Predominantly Buddhist, the Bamar ethnic group represents 60-70 percent of the population. Other religions in Myanmar include Animism, Christianity, Hinduism, and Islam. Muslims comprise an estimated 4 to 10 percent of the country's population and most live in Rakhine state. Many have been there for centuries; others arrived during the British colonial period (1824-1948).¹⁴

The majority of Muslims in Rakhine state are Rohingya, a singular ethnic group living along Myanmar's western border with Bangladesh and India. Their language (also called Rohingya) is derived from the Bengali language and resembles the Chittagonian dialect used in current Bangladesh.¹⁵ A second group of Muslims in Rakhine state – known as “Arkanese Muslims” or “Burmese Muslims” – speaks the Rakhine language and shares customs with Rakhine Buddhists.¹⁶ Myanmar also has other Muslim minorities who speak their own language and/or Burmese.

The Rohingya were considered citizens of Myanmar (then “Burma”) under the Constitution of 1948, when Britain ended its colonial rule and the country became an independent republic. However, the new government then set out to create a sense of nationhood that did not include all ethnic minorities. In 1962, the military junta took over Myanmar, and the Rohingya lost citizenship rights under the new Constitution of 1974.

Nearly a decade later, Myanmar's Citizenship Act of 1982 fully stripped the Rohingya of their citizenship rights. The new law required that citizens belong to one of 135 recognized “national races,” or provide evidence of family lineage in Myanmar before 1823 (or, in some narrow cases, 1948), among other stipulations. The list of “national races” excludes the Rohingya, and most members of the minority are unable to provide documentation that proves their ancestral history in Myanmar.

Although a nominally civilian government replaced the military junta in 2011, Myanmar continues to apply these citizenship requirements¹⁷ and to implement discriminatory laws and policies that have led to a breadth of human rights violations and have driven the Rohingya to flee Myanmar.¹⁸ These include: expropriation of land and forced eviction; confiscation and destruction of homes; forced labor; and restrictions on movement that affect access to education, health, and employment.¹⁹ While these laws and policies impact many ethnic groups, the Rohingya have been particularly affected, suggesting that they are targeted for their cultural and ethnic identity.²⁰

Increasing Waves of Violence (2012–2017)

June 2012

In 2012, violence in Myanmar erupted when a Rakhine Buddhist woman was raped and murdered, allegedly by Muslim Rohingya men. The conflict continued in 2013 with

several attacks on Muslim villages that ultimately uprooted 140,000 Rohingya, who became internally displaced people within Myanmar.²¹

Following these incidents, the then-president of Myanmar, Thein-Sein, told the visiting UN High Commissioner for Refugees that, since Myanmar was only responsible for third-generation Rohingya families, the agency should resettle the displaced Rohingya abroad or set up refugee camps to care for them.²²

In 2014, Myanmar's first country census in 30 years did not include the Rohingya as a recognized ethnic group and the government initiated a citizenship verification program,²³ whereby the Rohingya were instructed to register as "Bengali," an ethnic group native to India and Bangladesh.²⁴ Many Rohingya feared that registering as such would categorize them as "illegal" foreigners, so they resisted doing so.

Until 2015, the Rohingya were allowed to vote and hold public office; this shifted when a new law was passed requiring political leaders to be citizens – thereby excluding Rohingya candidates – and temporary identity cards used for voting were revoked for the November 2015 elections. As the first national vote since the end of Myanmar's 50-year military rule, the 2015 elections were particularly significant because the new parliament could choose Myanmar's next president.²⁵

In mid-2015, the Myanmar government announced a new citizenship verification process by which people would be given National Verification Cards (NVCs). Given the lack of transparency in the process's expected outcome and no option to self-identify as Rohingya, many refused to accept the NVC for fear of being registered as "illegal" and then expelled from Myanmar. By mid-July 2016, the government increasingly pressured the Rohingya to register for the NVC.²⁶

October 2016

Formed in 2013, the insurgent Arakan Rohingya Solidarity Army (ARSA) formally announced its existence on October 9, 2016 when it attacked three Border Guard Police (BGP) outposts with swords, spears, and homemade weapons, killing nine officers.²⁷ Following the attack on the police outposts, the ARSA's leader published a video saying that the Rohingya had faced abuses for 75 years and that "if the violence is not stopped, we have the right to defend ourselves."²⁸ The video specified that the group had not brought any harm to civilians, Rohingya or Rakhine.²⁹

A Muslim Rohingya man sits at his burnt home in a village in Rakhine state, Myanmar in October 2012.

*Photo: Soe Than
Win/AFP/Getty Images*



The following day, the Myanmar government claimed that the ARSA are “terrorists” and responded with military force, implementing a counterinsurgency “area clearance” campaign. This military-led offensive reportedly killed hundreds of Rohingya and burned at least ten villages, and also denied humanitarian assistance to those most affected.³⁰ Jointly conducted by the military and the BGP, these operations also recruited Rakhine Buddhist villagers to be part of a BGP training program, creating what could be de facto state-sanctioned vigilante activities.³¹

According to the International Organization for Migration, these “area clearance” operations drove an estimated 87,000 Rohingya into Bangladesh between October 2016 and July 2017.³²

*“You are Bengali, you have no place here.”
Rahama Bi Bi, 18-year-old woman (Profile 10), quoting
attackers*

August 2017

Under international pressure, the Myanmar government had set up the Advisory Commission on Rakhine State in September 2016. Composed of local and international experts and chaired by former UN Secretary-General Kofi Annan, the Commission was created to address increasing violence across Rakhine state. Hours before its recommendations were made public on August 25, 2017, the ARSA – armed primarily with knives and homemade bombs – raided 30 police outposts, killing 12 members of Myanmar’s security forces.³³

In response, the Myanmar military led a security crackdown that reportedly resulted in arrests, disappearances, beatings, stabbings, mass shootings, rape and sexual violence, looting, and the burning of Rohingya villages.³⁴ The military has denied responsibility for attacking Rohingya civilians, stating that its offensive was a counterinsurgency campaign focused on the ARSA. It said that the ARSA drove the Rohingya population out, destroying villages as it fled as part of a scorched earth policy.³⁵

The massacre in the village of Chut Pyin, which is the focus of this report, is one example of the violence that took place in August 2017 across Rakhine state and that led to more than 720,000 Rohingya fleeing Myanmar to Bangladesh from that month through June 2018.³⁶

*“As the Rakhines were our neighboring villagers, they
know us well. They know who were the mullahs and
teachers among us. So they killed them all. They didn’t
spare anyone.”
Sayed Alom, 21-year-old man (Profile 8)*

Rising Tensions in the Village of Chut Pyin³⁷

“[The] military have been troubling us [for] three years. ... The villagers could not sleep well. They had to guard the village day and night.”
Umma Salama, 23-year-old woman (Profile 18)

Located in Rathedaung Township in Myanmar’s Rakhine state, which borders Bangladesh to the north, Chut Pyin village consisted of two closely neighboring clusters of homes separated by ethnicity and religion: Rohingya Muslims to the southwest, and Rakhine Buddhists to the northeast.³⁸ There were roughly 1,400 Rohingya men, women, and children in Chut Pyin; the Rakhine Buddhist population are estimated to have been roughly one third of the Rohingya.³⁹ The villagers farmed household vegetables and rice, and most homes were made of thatched roofs, bamboo, and mud walls.

Rohingya leaders interviewed by Physicians for Human Rights (PHR) reported that the Myanmar security forces and Rakhine Buddhist leaders in Chut Pyin periodically⁴⁰ called them to attend meetings. The last of these was on August 22, 2017 and focused on the National Verification Card (NVC), for which the Rohingya were being pressured to register.⁴¹ Only Rohingya villagers who spoke Burmese were allowed to participate in this meeting, and one leader who attended reported seeing a flyer there that said: “If you see a boat with Rohingyas, kill them immediately.”⁴²

At this meeting, the Buddhist village leadership and Myanmar military from Light Infantry Division 33⁴³ forced Rohingya leaders to sign a paper committing them to consult their community on whether the villagers would accept registering for the NVC and to return with a collective decision in 24 hours. They also were told to warn Rohingya villagers that they would die if they rejected the NVC registration.⁴⁴

On August 23, 2017, the Rohingya Chut Pyin villagers collectively decided to reject the NVC. In response, they were told, “From now onwards, do not leave your houses, and if we see you on the road, we will shoot you.”⁴⁵ Rohingya villagers reported that the military then restricted their movement. One described how Myanmar security forces placed large stones throughout the village as posts, from where officers kept the Rohingya under surveillance.⁴⁶

“I will never go [back] there. The killers are there.”

Abaeda Khatu (Profile 14), 50, lost her husband, son, daughter-in-law, and grandson in the Chut Pyin massacre, all shot as the family fled towards the rice fields after the attackers unleashed their assault. Abaeda was shot in the leg and her 13-year-old daughter, Ayaesha (Profile 13), was struck in the hip; both lay in the fields for hours, surrounded by dead bodies, while the attack unfolded. They were finally found by neighbors who carried them to a nearby village. From there, they began the 14-day journey to safety in Bangladesh.

PHR’s forensic medical examination of Abaeda found a scar highly consistent with her report of being shot from behind as she fled Chut Pyin. An evaluation of Ayaesha’s x-ray

revealed a series of fragments still lodged in her hip, which are highly consistent with a bullet shattering on impact within her pelvis and which continue to cause her pain.

The Chut Pyin Massacre

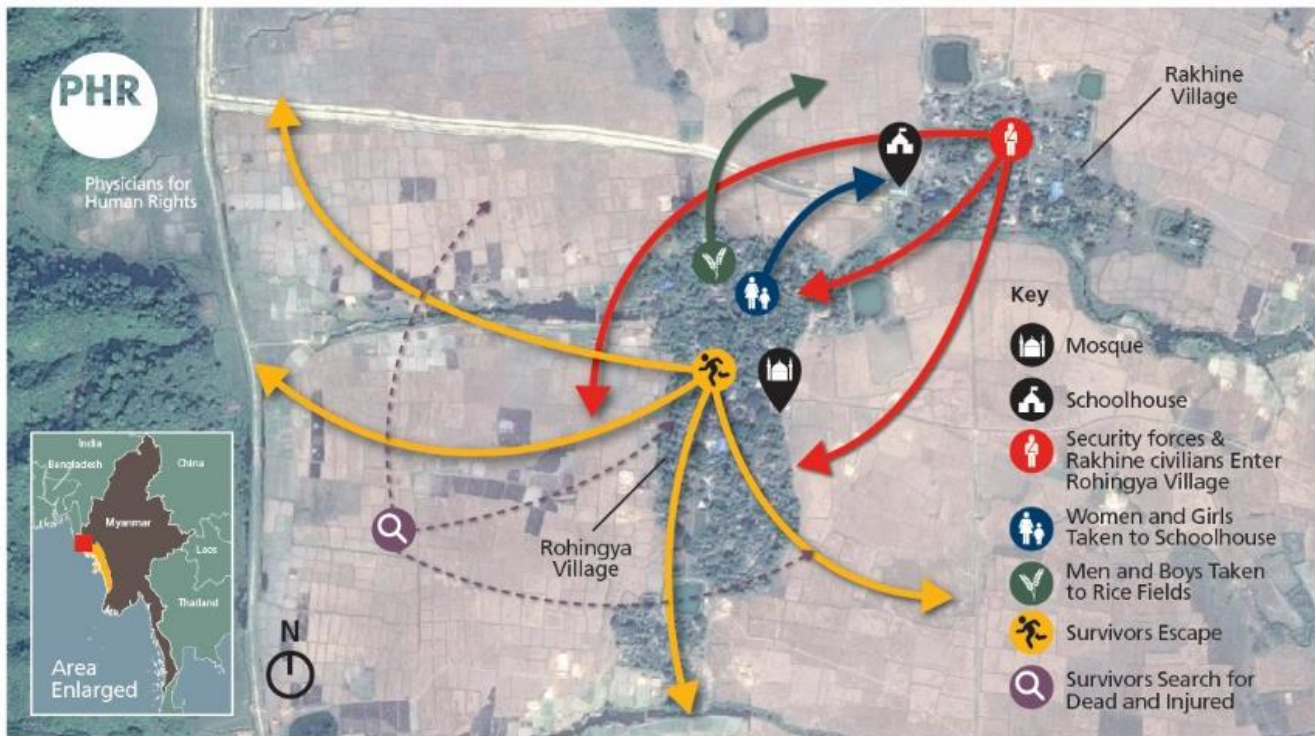
*“They attacked us and finished us within one day.”
Nur Asha, 20-year-old woman (Profile 6)*

The 25 survivors Physicians for Human Rights interviewed were consistent in their description of key elements of the attack unleashed on Chut Pyin on August 27. As Rohingya men returned from afternoon prayers around 1:30-2 p.m., Myanmar security forces and Rakhine Buddhist civilian villagers entered Chut Pyin. As they surrounded the village, they ordered the Rohingya to come out of their homes. The attackers shot people as they ran out, or inside their homes if they did not comply. The Rohingya houses were then looted or set on fire, or both.

Men and women were taken to separate areas of the village. Some men and boys were never seen again. Others were shot, and many of those lying injured on the ground had their throats slashed. Myanmar security forces and Rakhine Buddhist civilians were also seen slitting the throats of men who were kneeling. Women and girls, particularly those deemed young and attractive, were separated from men and other family members. They were then taken to the schoolhouse, where reportedly many were beaten, raped, and/or killed.

Many Rohingya tried to escape into nearby fields. Some were shot while running and others were shot, beaten, or stabbed when found hiding in the fields. Those who hid described being surrounded by several dozen bodies, many of them men with their throats slit and women with their breasts mutilated. Chut Pyin villagers, dead or alive, were stripped of any valuables such as jewelry, money, and cell phones.

The security forces and Rakhine Buddhist civilians who attacked Chut Pyin left after the sun had set. Survivors who hid or managed to escape the massacre then searched for their relatives, mostly in the fields. They took those who were still alive to neighboring villages, where some received medical care and were reunited with other relatives before trekking to the Cox’s Bazar area of Bangladesh – a voyage that took up to 10-12 days – in search of refuge.



Chut Pyin Massacre August 27, 2017

Out of Chut Pyin's Rohingya population of 1,400, it is estimated that some 400 villagers, including 99 children, were killed or are missing. Among them are a group of 50 men who were taken away and never seen again.



1:30 – 2:00 p.m.

As Rohingya men returned from afternoon prayers around 1:30 – 2:00 p.m., Myanmar security forces and Rakhine Buddhist civilian villagers entered Chut Pyin. As they surrounded the village, they ordered the Rohingya to come out of their homes. The attackers shot people as they ran out, or inside their homes if they did not comply. The Rohingya houses were then looted or set on fire, or both.



2:00 – 8:00 p.m.

Women and girls were separated from other family members. They were then taken to the schoolhouse, where many were beaten, raped, and/or killed. Men and boys were taken to the rice fields and beaten and/or killed.



2:00 – 8:00 p.m.

Many Rohingya tried to escape into nearby fields. Some were shot while running and others were shot, beaten, or stabbed when found hiding. Survivors described being surrounded by bodies, including men and boys with their throats slit and women with their breasts mutilated.



8:00 p.m. onwards

After the attackers retreated, villagers who had escaped returned to look for injured family members and to retrieve the bodies of the dead. Over the following weeks, survivors made the arduous journey to Bangladesh.



In Thangkali refugee camp in Bangladesh, Rohingya refugees Laila Baegum (Profile 1), 12, her five-year-old brother Shofiqul Islam (Profile 2), and her seven-year-old brother Anwar Sadak (Profile 3) show where they were shot by attackers who massacred their family and destroyed their village of Chut Pyin. Their grandmother (back) also survived, but their mother, father, and two other siblings were killed.

Photo: Salahuddin Ahmed for Physicians for Human Rights

Forensic Analysis

Of the 25 Chut Pyin villagers whom Physicians for Human Rights (PHR) interviewed, 22 had physical injuries and underwent a forensic examination; three additional testimonies came from witnesses and served as background information.

Ranging from five to 60 years of age, these 22 survivors were evenly split between male and female; 12 were adults (seven women and five men) and 10 were minors under the age of 18 (four girls and six boys). They sustained several different kinds of injuries, with some survivors sustaining multiple injuries. These included gunshot wounds (17); blunt force trauma such as kicking and beating (6); explosions/fragmentation such as shrapnel (3); penetrating injuries such as stabbings (3); and rape and sexual violence (1). All the forensic examinations and medical records were highly consistent with the events that the survivors described as having occurred within the previous six months.

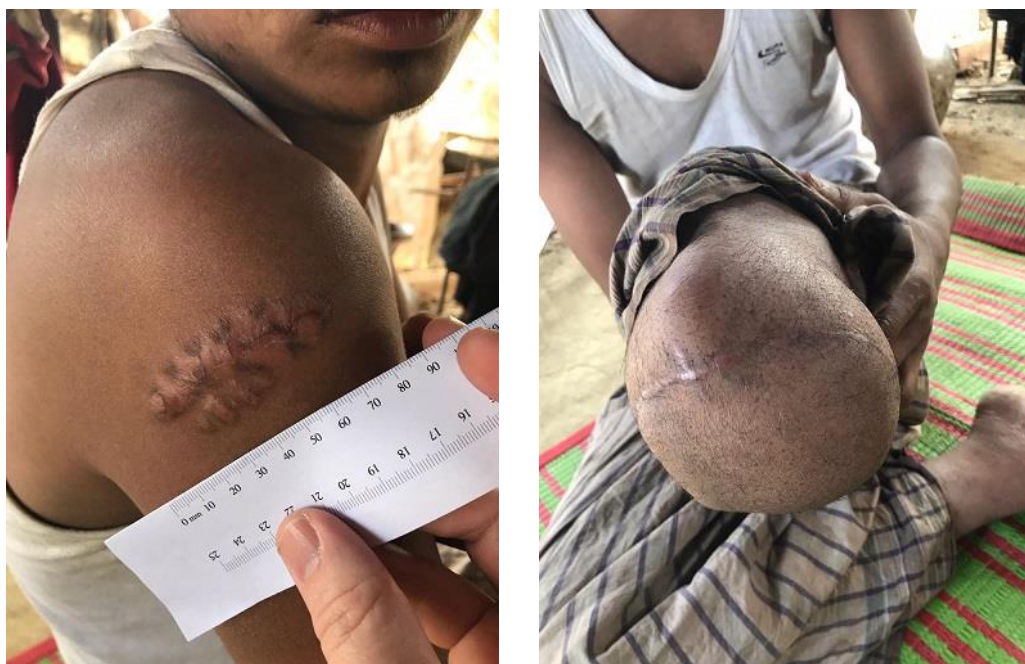Gunshot Wounds

Physical findings consistent with gunshot wounds were present in 17 of 22 survivors, who sustained a total of 21 gunshot wounds. These survivors ranged in age from five to 60 years old. These injuries uniformly reflected the survivors' narratives of being shot while attempting to flee, usually running away from the village toward a rice field or neighboring forest for protection.

In all these cases, the injury and resulting scars, both from the initial wound and any possible treatment, were highly consistent with projectile injuries. This assessment was based on: 1) the shape and size of the entry wound, often round or oval; 2) the existence

of exit wounds that were larger or more macerated; 3) the presence of surgical incisions or healing sites; 4) the progression of wound healing; and 5) the existence of internal, bone, or muscle damage from the projectiles. In particular, the consistency in the size of the initial entry wounds in the survivors, about 0.5 cm in diameter, suggests that several shooters used bullets that were similar in size.

Almost half of the survivors who sustained gunshot injuries (9/17) had their mobility permanently affected – two survivors have persistent pain while trying to walk, and seven of the survivors now face some form of physical disability. These conditions range from walking with a cane or a stick to a limb amputation.



19-year-old Sultan Ahmed (Profile 9) was shot in the right shoulder and left ankle as he fled his home in Chut Pyin. After he arrived in Bangladesh, his lower left leg was amputated.

Photos: Physicians for Human Rights

Blunt Force Trauma (Hitting, Beating, Kicking)

"After shooting, they kicked me three times. ... I pretended to be dead without moving at all. That's why they left me. To some people who were alive, they stepped on and broke bones."

Nur Asha, 20-year-old woman (Profile 6)

Nearly a quarter of the survivors interviewed (6/25) reported having been kicked or beaten during the attack on Chut Pyin, and almost half of them (13/25) reported having witnessed the infliction of blunt force trauma. While it may not leave long-term external scars, this type of violence can be debilitating and can cause significant internal injuries. For instance, 20-year-old Abdul Roshid (Profile 21) was shot as he ran through gunfire and hid by a pond, from where he witnessed people being killed and women being

raped. Three men then found him; while they held him at gunpoint, he was stepped on and kicked in the left side of the chest, torso, and leg. He suffered nerve damage in his left leg and is permanently disabled and unable to support his family.



22-year-old Abdul Roshid (Profile 21) was shot and beaten during the attack on Chut Pyin and is permanently disabled. During his examination by PHR's clinical team, he showed signs of depression and post-traumatic stress disorder. Photo: Physicians for Human Rights

Blast Explosions and Fragmentation

Three people sustained injuries from explosives or fragmented projectiles during the Chut Pyin massacre: Mohammed Yusuf, a five-year-old boy (Profile 16) who permanently lost his sight and hearing on the right side; Anayath Korim (Profile 15), 20, who walks with a limp and has limited joint range of motion due to permanent burn scars; and 17-year-old Mohammed Isaq (Profile 5), who had to be operated on and hospitalized for five months and still walked with crutches six months after the attack.

PHR's physical findings suggest that these two survivors' injuries could have been caused by the impact of a hand grenade or a launched projectile, such as a mortar or a propelled grenade. Such weapons can cause severe burns, bone fractures, and internal injuries. Shrapnel or other object fragments within the wound, dirt, or other nearby objects may also cause infections that, depending on their severity, can eventually lead to disability.

Blinded While Playing Near Chut Pyin

Five-year-old Mohammed Yusuf (Profile 16) and his older brother were playing near Chut Pyin when he heard gunfire and explosions close to him, followed by a sudden pain in his right eye. His brother carried him home to their mother, who saw that Mohammed's eye was covered with blood. Now in Bangladesh, Mohammed cannot see out of his right eye nor hear out of his right ear.

PHR's physical examination of Mohammed found that his right eye is nonreactive to light and that he has conductive hearing loss in the right ear, both symptoms consistent with Mohammed's account of exposure to explosions and blast trauma.



Five-year-old Mohammed Yusuf (Profile 16) was playing near Chut Pyin when he was hit by an explosion and felt a pain in his right eye. He is completely blind in that eye and cannot hear out of his right ear. He was examined by Homer Venters, MD, part of the PHR clinical team that conducted forensic medical examinations at Thangkali refugee camp in Bangladesh.

Photo: Salahuddin Ahmed for Physicians for Human Rights

Penetrating Injuries (Stabbing, Slashing, Mutilation)

*“They shot the young men dead.... [The military] shot them with guns and [the] Rakhines slit throats.”
Sayed Alom, 21-year-old man (Profile 8)*

Two women described being stabbed with a knife attached to the end of a gun. Hala Banu (Profile 19), 35, was held at the school, where attackers took her valuables and then told her to leave. She froze in shock, so a soldier stabbed her below the breast. Similarly, 20-year-old Kismath Fatima (Profile 20) said she was stabbed in the forearm with a knife attached to a gun when she tried to resist being gang-raped in the school.

Four testimonies refer to attackers slitting the throats of young men who had been injured by gunshots but were still alive. Other survivors reported the killing of boys and men who were kneeling and therefore already surrendering to the attackers. PHR did not have access to Chut Pyin to examine the bodies of those killed, but 10 witnesses consistently described having seen dead men with slit throats, and five witnesses reported seeing women with their breasts cut off or mutilated.

Tormented By Flashbacks of Her Murdered Husband and Son

As the attackers swarmed into Chut Pyin, Hala Banu's (Profile 19) family tried to escape out the back of their house, but her husband and six-year-old son were shot dead just steps away. Hala's nine-year-old daughter, Somaiya (Profile 7), was shot in the leg and couldn't run; she lay bleeding by the bodies of her father and brother as security forces

struck Hala in the face with a metal rod and dragged her away to the schoolhouse. At the school, Hala found women screaming and crying. She saw two women being raped, and the baby of one of the victims being thrown into a fire. After her attackers forced Hala to turn over her jewelry, they stabbed her with a knife attached to the end of a gun. She managed to run out of the building and back to her home, where she found Somaia still alive. Mother and daughter were finally rescued and taken to a nearby village. From there, they set out on an arduous 12-day walk to Bangladesh, Somaia's older brother and a cousin carrying her in a blanket through heavy rains and mud up to their thighs.

PHR's forensic medical examination of Hala found scars highly consistent with her account of being struck in the face and stabbed; Somaia's leg bore scars typical of bullet entry and exit wounds. Hala's affect throughout her evaluation was one of depression and anxiety; she described having nightmares and other psychological symptoms which are highly consistent with a diagnosis of post-traumatic stress disorder.

Rape and Sexual Violence

Twenty-year-old Kismath Fatima (Profile 20) described how she was gang-raped on the floor of the school: after her attackers blindfolded her and tied her hands and legs, they forced her to lie down and then beat her in the head, face, shoulders, and torso with a gun.

Kismath cannot remember how many times she was raped, but she suffered blunt force trauma and penetrating injuries. The assailants groped, slapped, and kicked her in the face whenever she tried to resist by moving away. One of the men also stabbed her right forearm with a knife attached to the end of a gun.

Hours later, Kismath and five women were let go from the school where they were being held; they ran to the forest naked. She reported that she could barely move due to pain, heavy vaginal bleeding, and bruising in the following hours and days. Six months after the attack, Kismath still reported persistent dull abdominal pain and nightmares.



Sultan Ahmed (Profile 9) indicating the pond he hid in near the schoolhouse, where he saw dozens of women and girls taken during the attack on Chut Pyin. Many were raped and killed. He heard them crying "Oh, father, oh, mother, come and save us!" and saw a woman with mutilated breasts. Sultan also overheard orders that all Rohingya men and boys be killed. He said those who did not die from bullet wounds had their throats slit.

Photo: Physicians for Human Rights

Psychological Distress

All survivors interviewed by PHR detailed the intense scope and scale of violence they faced or witnessed, and almost a third (6/22) reported or showed strong symptoms (crying, nightmares, and dissociation) of mental health diagnoses – including post-traumatic stress disorder (PTSD), anxiety, and depression.

Uma Salama (Profile 18) shared how Myanmar security forces had hit her and then tied her to a tree, yelling, “Don’t cry.... If you cry, you will be killed.” The 23-year-old woman then witnessed attackers set fire to her house and shoot four family members; a bullet also grazed her leg from behind. Throughout her testimony, Umma had a flat affect and was crying quietly while pulling on the strings of her shawl. Her emotional affect was clinically consistent with significant psychological trauma.

The impact of these events upon children for sustained psychological distress is particularly concerning. A helicopter flew over during an interview with a survivor in Thangkali refugee camp and several children in the vicinity became visibly agitated and afraid. They pointed to the sky shouting, “Myanmar is coming towards us!”⁴⁷ In another interview, 12-year-old Mohammed Aziz (Profile 22) told PHR that he wakes up every night crying and screaming, and his mother has to help him settle down. Mohammed was shot inside his home and ran out just before his house was burned down. While hiding by a pond, he saw attackers take valuables from dead bodies and beat those who were still alive. He also saw attackers hit his own brother in the head; the brother is now deaf in his right ear.

Social support from family and a broader community has a positive influence on the ability to cope with a trauma. However, many survivors lack such support: Shobbir Alom, a witness to the Chut Pyin massacre who did not sustain any injuries, lost 10 family members.⁴⁸ Additionally, 13 of the 22 survivors with injuries reported that they lost a total of 25 relatives. For instance, 13-year-old Ayaesha Siddiq (Profile 13) lost her father, brother, sister-in-law, and nephew in the attack. Only she and her mother survived. Likewise, six members of Rabia Basri’s (Profile 4) family were shot dead while trying to escape. Two survivors had a disappeared family member they presumed dead; 19-year-old Sultan Ahmed (Profile 9), for instance, shared with PHR that neighbors said that his father was taken and killed, but he did not know any further details.

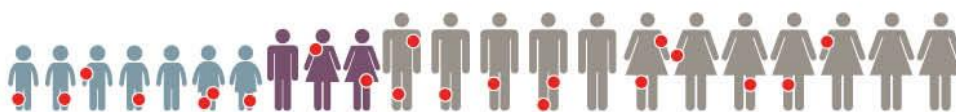Please see page 33 for the full dossier of case profiles and forensic evaluations.

Chut Pyin Massacre

Survivor Statistics from PHR Evaluations

No.	Age	Gender	Alias	Mobility Permanently Affected	No. of Gunshot Wounds	Blunt Force Trauma	Explosion/ Fragmentation	Sexual Violence	Stabbing/ Mutilation	Family Members Lost
1	12	Female	Laila Baegum	—	●●	—	—	—	—	●●●●●
2	5	Male	Shofiqui Islam	—	●	—	—	—	—	Sibling of Profile 1
3	7	Male	Anwar Sadak	—	●	—	—	—	—	Sibling of Profile 1
4	21	Female	Rabia Basri	●	●●	—	—	—	—	●●●●●●●
5	17	Male	Mohammed Isaq	●	—	—	●	—	—	—
6	20	Female	Nur Asha	●	●	●	—	—	—	●
7	9	Female	Somaiya Akter	●	●	—	—	—	—	●●
8	21	Male	Sayed Alom	●	●	—	—	—	—	●
9	19	Male	Sultan Ahmed	●	●●	●	—	—	—	●
10	18	Female	Rahama Bi Bi	—	●	—	—	—	—	—
11	10	Male	Rahamed Ullah	—	●	—	—	—	—	—
12	17	Female	Jahan Ara	●	●	—	—	—	—	●●
13	13	Female	Ayaesha Siddiqa	—	●	—	—	—	—	●●●●●
14	50	Female	Abaeda Khathu	—	●	—	—	—	—	Mother of Profile 13
15	20	Male	Anayath Korim	—	—	—	●	—	—	—
16	5	Male	Mohammed Yusuf	●	—	—	●	—	—	—
17	60	Male	Mohammed Yasin	—	●●	—	—	—	—	—
18	23	Female	Umma Salama	—	●	●	—	—	—	●●●●●
19	35	Female	Hala Banu	—	—	●	—	—	●	Mother of Profile 7
20	20	Female	Kismath Fatima	—	—	●	—	●	●	—
21	22	Male	Abdul Roshid	●	●	●	—	—	—	—
22	12	Male	Mohammed Aziz	—	●	—	—	—	●	—
Subtotal				9	21	6	3	1	3	25

17 of 22 survivors
suffered at least one
gunshot wound



7 survivors were
12 or younger



3 survivors were
13 to 17



12 survivors were
18 or older





13-year-old Ayaesha Siddiq's (Profile 13) father, brother, sister-in-law, and nephew were all killed in the Chut Pyin attack. She was shot in the hip as she fled, an injury that left shrapnel in her body and continues to cause her pain when she walks.

Photo: Salahuddin Ahmed for Physicians for Human Rights

Human Rights Analysis

"Don't spare a single man or boy of Chut Pyin village. Kill them all."

Sultan Ahmed, 19-year-old man (Profile 9), quoting attackers

Allegations of Crimes against Humanity

For years, Physicians for Human Rights (PHR) and many other highly credible organizations have documented the plight of the Rohingya in Myanmar. Since the two latest waves of violence against the Rohingya in October 2016 and August 2017, reports on this human rights and humanitarian crisis have increased.

In September 2017, the Office of the High Commissioner for Human Rights at the United Nations (OHCHR) went as far as to describe the attacks as "a textbook example of ethnic cleansing"⁴⁹ and several human rights non-governmental organizations have stated publicly that Myanmar's human rights violations against the Rohingya amount to crimes against humanity.⁵⁰

The founding treaty of the International Criminal Court (ICC), the Rome Statute,⁵¹ enumerates the following acts as crimes against humanity: murder, extermination, enslavement, deportation or forcible transfer of populations, imprisonment in violation of international law principles, torture, sexual violence, persecution of any identifiable group or collectivity, enforced disappearance, apartheid, and other inhumane acts

intentionally causing great suffering or serious injury to body or to mental or physical health.

Overall, to determine whether acts constitute a crime against humanity, two main elements must be established: 1) that these acts were committed as part of a widespread or systematic attack directed against a civilian population; and 2) that the perpetrator participated in and had knowledge of the attack.⁵²

Myanmar is not a party to the Rome Statute, so only the UN Security Council can refer Myanmar to the ICC for further criminal investigation.⁵³ Moreover, in June 2018, an ICC prosecutor asked the Court to consider whether prosecution could take place through Bangladesh, which is a party to the Rome Statute.⁵⁴

PHR's research and analysis in this report indicate that the grave human rights violations committed in Chut Pyin should be investigated as potential crimes against humanity (namely murder and enforced disappearances, torture, rape and other sexual violence, and forcible transfer of populations).

Murder and Enforced Disappearances

"I saw they threw a two- or three-month-old baby into the fire. When the mother cried aloud, they shot the mother dead."

Hala Banu, 35-year-old woman (Profile 19)

All governments carry a duty to abstain from violating human rights and the positive obligation to protect human rights.⁵⁵ The International Covenant on Civil and Political Rights (ICCPR), a core international human rights instrument ratified by 171 UN member states, establishes that "every human being has the inherent right to life."⁵⁶ While Myanmar has not yet ratified the ICCPR, it is party to the Convention on the Rights of the Child,⁵⁷ the Convention on the Elimination of All Forms of Discrimination against Women,⁵⁸ and the Convention on the Rights of Persons with Disabilities,⁵⁹ all of which include the right to life. This right is also enshrined in the Universal Declaration of Human Rights, largely accepted as a common standard for all nations and adopted by all UN member states, including Myanmar.⁶⁰

All Chut Pyin survivors interviewed by PHR reported having witnessed a relative or neighbor being killed, in some cases several people at once, pointing to the perpetration of mass killings. PHR research shows that 13 out of the 22 survivors lost 25 family members; in addition, a survivor who did not sustain injuries lost 10 relatives. According to a media report, one survivor from Chut Pyin has compiled a list of more than 350 missing or dead villagers, of whom 99 are young children or babies who were killed because they were unable to run fast enough to escape their attackers.⁶¹ Another 50 men are disappeared and presumed to be detained or dead. Overall, this represents roughly one third of Chut Pyin's estimated Rohingya population of 1,400 people.

"My husband went missing [after] he went out for afternoon prayers. I still don't know whether ... he was arrested or whether he was slaughtered."

Nur Asha, 20-year-old woman (Profile 6)

In addition to shootings, Chut Pyin survivors described attackers using long knives (often used to slaughter livestock) to execute Rohingya villagers by slitting the throats of those wounded on the ground or those kneeling in submission. One survivor reported seeing a baby thrown into a fire and another saw a dead body thrown into a fire, indicating a possible intention by the attackers to cover up evidence of the killings.

Those who survived by hiding in fields or in the forest for hours pretended to be dead when approached by Myanmar security forces to avoid being killed. Most described being surrounded by dozens of bodies of men, women, children, disabled people, and the elderly, indicating the indiscriminate killings of civilians, contrary to reports by the Myanmar military.⁶²

“If you cry, you will be killed.”

On the day of the massacre, Myanmar security forces surrounded 23-year-old Umma Salama’s (Profile 18) home and ordered her family to come out. They hit Umma in the head with a gun and then took her away and tied her to a tree, shouting “Don’t cry... If you cry, you will be killed.” While she was tied up, Umma saw security forces set fire to her house, and her husband, brother-in-law, daughter, and son shot dead as they tried to run away. She witnessed several other villagers shot dead and a bullet grazed her leg. Hours later, Umma’s mother-in-law was able to untie her from the tree. They hid in the forest and then went to a neighboring village, where they met others from Chut Pyin. A week later, they began walking to Bangladesh.

PHR’s medical examination found a scar on Umma’s leg highly consistent with her narrative of being grazed by a bullet while tied to the tree. Throughout her evaluation, Umma had a flat affect, with tears flowing down her face. She pulled repeatedly at a string on her shawl and made limited eye contact, demeanor highly consistent with the psychological effects of the trauma that she described.

Torture and Other Cruel, Inhuman, or Degrading Treatment or Punishment

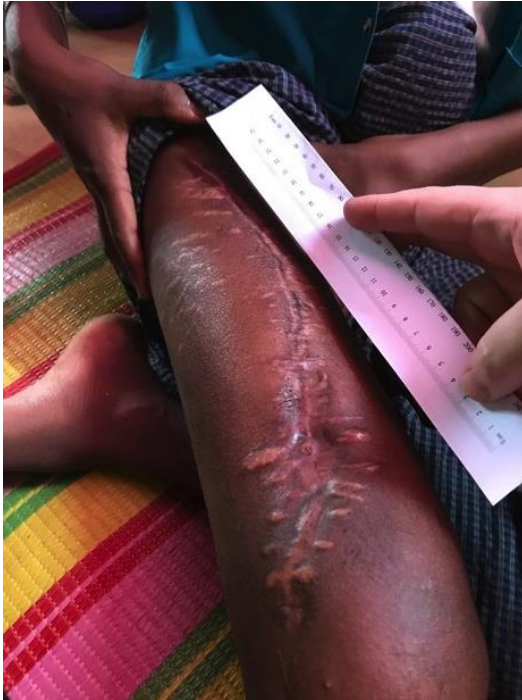The Convention against Torture (CAT) defines torture as occurring when “intentional severe mental or physical pain or suffering is inflicted to intimidate or coerce someone with the involvement of someone acting in an official capacity.”⁶³ According to the UN Special Rapporteur on Torture, physical or mental pressure or coercion in a situation of detention or similar direct control constitutes at least cruel, inhuman, or degrading treatment.⁶⁴

Although Myanmar has not ratified the CAT, nor recognized other instruments that define ill-treatment, the prohibition against torture is so absolute and universally accepted that it is considered a fundamental principle of customary international law, which binds all nations. As a result, torture is unacceptable under any circumstance.⁶⁵

Chut Pyin survivor testimonies and PHR’s examination of the abuse they suffered are consistent with allegations of torture or other cruel, inhuman, or degrading treatment or punishment in the form of threats, insults, blindfolding, forced witnessing of the abuse of others, beatings, stabbings, throat slashing, rape, and other sexual violence such as breast mutilations.

The most visible psychological impact upon the survivors was observed in those who had suffered blunt force trauma. In three of the six cases, this type of violence was used as punishment for not complying immediately with the attackers' orders (Profiles 18, 19, and 20). In four of the six cases, the survivors reported symptoms of post-traumatic stress disorder (PTSD) while they shared their testimony (Profiles 18, 19, 20, and 21).

For instance, Hala Banu (Profile 19) described having just seen her husband and six-year-old son killed and then being hit in the head with a metal rod for trying to resist being taken to the school where women faced sexual violence. Once there, she was forced to keep her head down in the mud as punishment. As she shared her testimony with PHR, Hala had a depressed and anxious emotional affect, crying as she described nightmares and symptoms of depression.



Mohammed Isaq (Profile 5), 17, was shot inside a house where he sought shelter when shooting began. After a 12-day journey to Bangladesh, he was hospitalized for five months and underwent multiple surgeries with rods and screws in his leg. Six months later, he cannot bear weight on that leg and still requires crutches to walk.
Photo: Physicians for Human Rights

“They tortured us a lot.”

As the massacre in Chut Pyin unfolded, Kismath Fatima (Profile 20) was taken from her home to the school, where she was robbed of her jewelry and tied by her arms and legs. Blindfolded and forced to lie down, she was raped repeatedly. Whenever she resisted, Kismath's assailants kicked her in the face and beat her with a gun, and then stabbed her in the arm with a knife. After hours of being held and gang-raped – Kismath does not remember how many times – she and five other women fled, though they could barely walk due to pain. Kismath had to be carried to a neighboring village to seek medical care. She suffered heavy bleeding and bruising in the following hours and days. Six months later, she still had persistent dull abdominal pain and was plagued by nightmares.

PHR's medical evaluation found that Kismath had a scar typical of a stab wound, where significant pressure from the knife had also crushed surrounding skin tissue. She cried throughout the interview, maintained a dull affect, and reported having nightmares – all behavior consistent with depression or post-traumatic stress disorder.

Rape and Other Forms of Sexual Violence

Rape and other forms of sexual violence have been defined as torture.⁶⁶ The Myanmar military's use of sexual violence as a tactic to drive the Rohingya out of the country has been well documented since the 1990s and continues to be used as a tactic today, demonstrating the ongoing nature of this practice.⁶⁷

Chut Pyin accounts consistently describe the separation of women and girls deemed young and attractive from men and other family members. While the men were taken away – many never seen again – the women and girls were brought to the schoolhouse. There, they were beaten, raped, killed and/or mutilated, or were forced to watch this abuse being inflicted on others.

Nine of the 25 Chut Pyin villagers interviewed reported hearing crying and screaming from inside the school, such as “Oh, father, oh, mother, come and save us!”⁶⁸

One witness reported seeing a woman leaving the school bleeding from her groin, and Hala Banu (Profile 19) reported witnessing two women being raped there.

Kismath Fatima (Profile 20) described how she was tied up and gang-raped by several men on the floor of the school. Her attackers repeatedly groped her body, and, whenever she tried to move away, they slapped and kicked her face. They also beat her in the head, face, shoulders, and torso with a gun. One man stabbed Kismath's right forearm with a knife attached to the end of a gun.

Persecution and Deportation or Forcible Transfer of Population

*“You are not citizens – you are Bengali and we will kill you. We will destroy you. Accept the NVC [National Verification Card] if you want to stay in our country.”⁶⁹
Anis Ullah, 55-year-old man, quoting Myanmar security forces at a meeting with Chut Pyin villagers days before the attack*

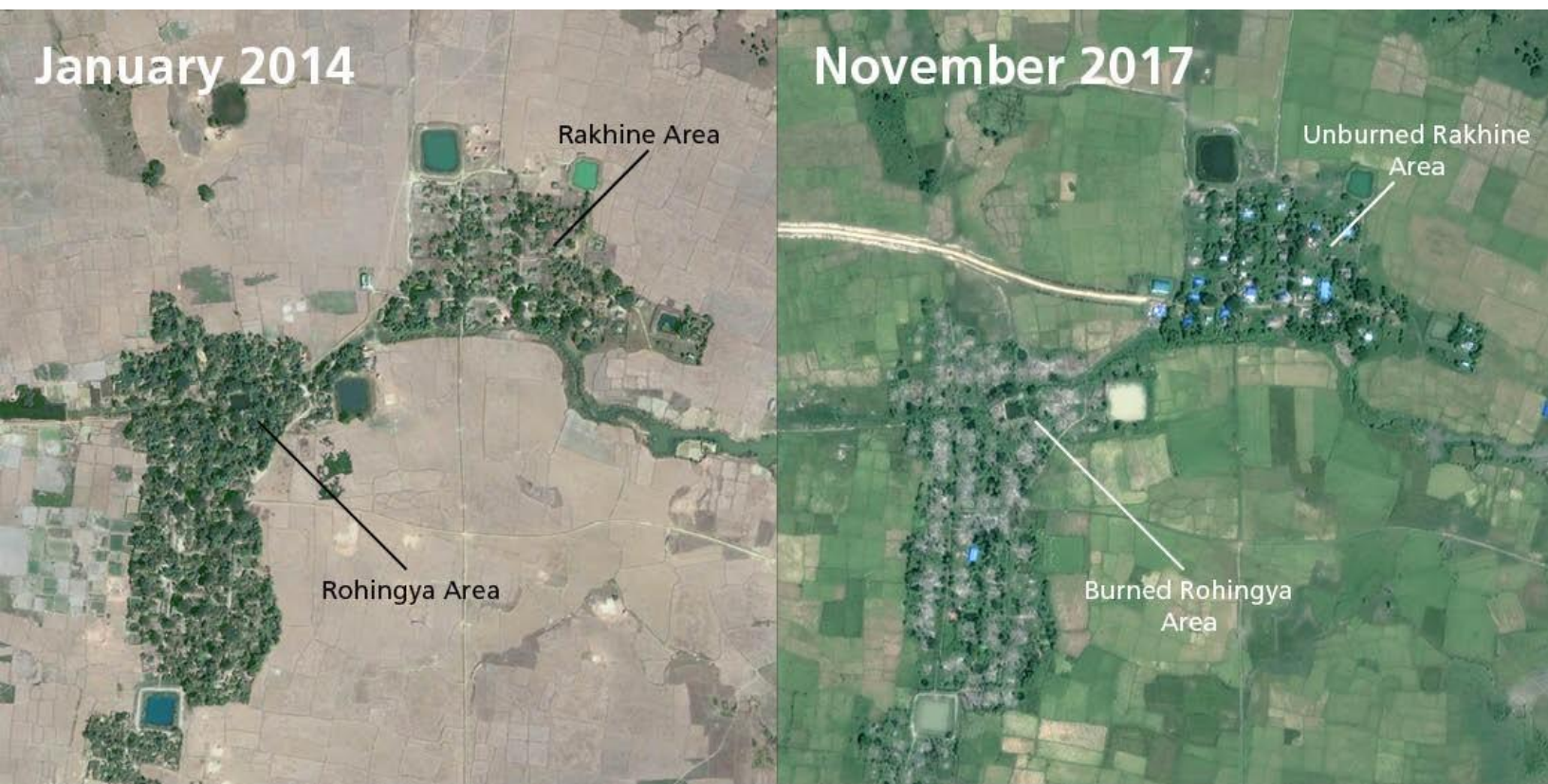The human rights violations committed in Chut Pyin seem to have been a part of a widespread campaign to drive the Rohingya out of Myanmar in August 2017, similar to the so-called “clearance operations” the Myanmar military conducted in October 2016.⁷⁰ Among the elements of the ICC's definition of deportation or forcible transfer is the “threat of force or coercion, such as that caused by fear of violence, duress, detention, psychological oppression or abuse of power against such person or persons or another person.”⁷¹ The Myanmar security forces and the Rakhine Buddhist civilians who participated in the attack on Chut Pyin indicated these intentions before, during, and after the massacre.

PHR gathered several testimonies that reflect how threats against the Rohingya in the days leading up to the massacre in Chut Pyin point to a potential imminent attack upon the population. Five days before the attack, Myanmar officials at the last Chut Pyin meeting on August 22 reportedly threatened Rohingya leaders and the community at large: “If you do not accept the NVC [National Verification Card], you cannot stay here. If you stay, we will finish you all and empty this place. We will clean the area.”⁷² These military leaders then referred to other townships that had been destroyed, warning that

the “people did not listen,” and that therefore authorities “killed men, women, and children”⁷³ – indicating a possible attack on Chut Pyin as part of a broader campaign to drive the Rohingya population away.

Out of the 21 villages visible by satellite in August 2017 in the township of Rathedaung where Chut Pyin is located, only five villages remained by mid-September.

All adult Rohingya survivors also stated that both the Myanmar security forces and Rakhine Buddhist civilians burned the Rohingya part of the village. These accounts follow a pattern of an ongoing campaign against the Rohingya: PHR interviewed Rohingya leaders from three neighboring villages that also faced attacks in the days following the Chut Pyin massacre.⁷⁴ Satellite imagery confirms the scope and scale of this destruction: out of the 21 villages visible by satellite in August 2017 in the township of Rathedaung where Chut Pyin is located, only five villages remained by mid-September.⁷⁵ Moreover, in what seems to demonstrate discriminatory intent against the Rohingya, an analysis of satellite imagery shows that the Rohingya section of Chut Pyin (lower left in the images below) was burned, while the Buddhist sector (upper right) remained intact.



The village of Chut Pyin, Myanmar in January 2014 (left) and November 2017 (right), after Myanmar security forces and Rakhine Buddhists burned the Rohingya section of the village (lower left in each image) to the ground. The Rakhine Buddhist section of the village (upper right) remained intact.

Photos: DigitalGlobe via Getty Images

Denial of Access to Medical Care: Violations of Protections for the Sick and Wounded

“The military ... searched the houses of the doctors and asked the family to take out the people injured with bullet wounds.”

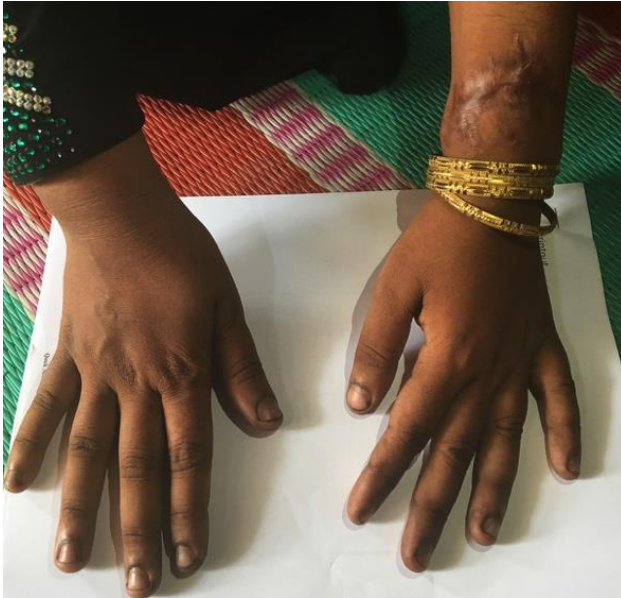Nur Asha, 20-year-old woman (Profile 6)

Myanmar is party to the International Covenant on Economic, Social and Cultural Rights,⁷⁶ which obligates governments and individual health care professionals to fulfill the right to health and to respect the principles of non-discrimination, including in times of emergency.⁷⁷

Access to health care was severely limited for those who survived the attack in Chut Pyin. Sixty-year-old Mohammed Yasin (Profile 17) told PHR that he sought medical care for a gunshot wound in a neighboring village, where a doctor warned him that Myanmar security forces had instructed doctors to report anyone who arrived wounded. Mohammed was told that at least 50 wounded people had already been detained, so it was likely that Myanmar security forces would return to inquire whether more Chut Pyin villagers had arrived seeking assistance. Nur Asha (Profile 6), who was shot in the wrist, also reported hearing a doctor say that soldiers would search for doctors in order to arrest wounded Rohingya survivors. “They looked for people with bullet wounds in order to erase the evidence,” she said “We are the witnesses to reveal their crimes, [so] they wanted to kill those survivors.”

More than half of the survivors interviewed who sustained injuries (12/22) only received adequate medical care after crossing the border into Bangladesh, up to two weeks after the massacre. At least 10 of them had to be carried to the neighboring country because they were unable to walk on their own due to their injuries. The journey typically took up to 10 to 12 days, which likely exacerbated infections and other ailments. Many survivors described traveling through forests, rivers, and mud up to their thighs with foul-smelling or inflamed wounds. These worsening symptoms were likely due to the poor conditions of travel and delays in medical care faced by the survivors.

Six months after these survivors fled Chut Pyin, nine of the 22 who were physically evaluated still had chronic pain, limited range of motion, and weakness or contractures (shortening) of the bones, muscles, or skin, among other physical limitations. Jahan Ara (Profile 12), 17, who was shot in the left shoulder and then kicked, reported that her condition improved after surgery in Bangladesh but that she faced subsequent deterioration in mobility and persistent pain. Her experience is likely the consequence of delayed access to adequate medical care and subsequent rehabilitation.



Twenty-year-old Nur Asha (Profile 6) escaped the attack on Chut Pyin with her two children, but was shot as she fled. The bullet killed one of her children and then entered her left wrist, which required surgery when she arrived in Bangladesh. “I will never forget what happened to me,” she said. “I am always thinking about it.”

Photo: Physicians for Human Rights

Myanmar’s Response

The Myanmar authorities have largely denied responsibility for the events of August 2017, including those that took place in Chut Pyin. In September 2017, Myanmar officials explained the killing of the Rohingya as “some of the ethnic natives while on their way were brutally butchered by the terrorists applying inhuman ways without any reason.”⁷⁸ In November 2017, the Myanmar military published the official results of an internal investigation, acquitting itself of any wrongdoing: “Security forces did not commit shooting at innocent villagers and sexual violence and rape cases against women. They did not arrest, beat and kill the villagers.”⁷⁹

The following year, in April 2018, the Myanmar military announced that another internal investigation had led to the dismissal and sentencing to prison of four officers for the September 2017 killing of 10 Rohingya men in the village of Inn Din in northern Rakhine state. While this could have been a step forward towards conducting more widespread investigations, the journalists who reportedly uncovered key information were charged under the Official Secrets Act and detained,⁸⁰ and the Myanmar authorities did not address other documented incidents related to attacks on Rohingya villages.

The Myanmar military has failed to acknowledge its role in the Chut Pyin massacre, yet all of the villagers interviewed by PHR reported that Myanmar security forces carried out the attack with the assistance or direction of Rakhine Buddhist villagers, whom many survivors recognized as neighbors. For example, 10 of the 25 interviewees reported seeing the Rakhine Buddhist village administrator ordering men and women be taken to separate areas of the village, among other instructions that led to a host of human rights violations. Another two witnesses reported seeing Myanmar soldiers throw a baby and a dead adult into a fire, which could have been an attempt to destroy evidence of killings and other abuses.

Moreover, Chut Pyin survivors described how, days prior, they had been threatened with a potential crackdown if they did not accept registering for the National Verification Card, suggesting that the attack was being planned. The attack also was implemented in a remarkably similar pattern to what the OHCHR documented in attacks

on five Rohingya villages in October 2016, pointing to a trend in the Myanmar military's tactics against the Rohingya:⁸¹ "The Myanmar army would arrive with other armed men, who would burn and loot the village. Men were separated and often beaten or taken away, while women were taken to a school or other building, where many would be raped or face other forms of sexual violence. Those fleeing were shot or knifed, including babies, toddlers, children, women, and the elderly."⁸² Moreover, survivors cited by the OHCHR reported the absence of emergency health care, including for victims with critical injuries resulting from gunshots, knife attacks, burning, rapes, and beatings.⁸³ This is consistent with statements made by all Chut Pyin survivors interviewed by PHR, and verified by other sources.⁸⁴

To date, Myanmar authorities have failed to conduct a full and independent investigation into attacks and have not fully cooperated with others seeking to do so.⁸⁵ In June 2018, the Myanmar government announced the creation of an "independent commission of inquiry" to investigate allegations of human rights abuses by the Arakan Rohingya Solidarity Army (ARSA) and "related abuses."⁸⁶ However, the credibility and impartiality of these efforts are doubtful, given the Myanmar government's history of failing to undertake objective human rights investigations.

A United Nations fact-finding mission on Myanmar, created in 2017 to investigate incidents related to the Rohingya crisis, was barred from entering the country. Myanmar also denied the UN-appointed special rapporteur on the situation in Myanmar, Yanghee Lee,⁸⁷ any further access or cooperation following her critical report in July 2017. To PHR's knowledge, no international organization or body has had access to villages reportedly destroyed to investigate allegations of human rights violations and prosecute those responsible.

Conclusion

A range of human rights violations took place in the Myanmar village of Chut Pyin, including killings and executions; detentions and disappearances; physical assault involving beatings, stabbings, and other forms of violence; rape and other sexual violence; ethnic and religious discrimination; and forcible displacement followed by looting and burning of homes. Several survivors interviewed by Physicians for Human Rights (PHR), among them many women and children, faced multiple violations.

Based on the consistent and detailed testimony of Chut Pyin survivors and forensic examinations conducted by PHR, as well as corroborating information from additional credible sources and the history of the Rohingya in Myanmar, PHR concludes that Chut Pyin is an example of the campaign that Myanmar authorities have carried out against the Rohingya people, and that the involved acts should be investigated as crimes against humanity.

Several human rights organizations have called on the United Nations Security Council to refer Myanmar to the International Criminal Court (ICC) to be investigated for alleged crimes against humanity. In June 2018, the ICC sent a request to Myanmar to exercise jurisdiction over the alleged crime of deportation. Given the cross-border nature of the Rohingya crisis, an ICC prosecutor also asked the Court to consider prosecution through Bangladesh, which is a state party to the Rome Statute of the ICC and therefore is subject to its jurisdiction.⁸⁸

Beyond the ICC, crimes against humanity are also subject to universal jurisdiction, whereby a third country can hold suspected perpetrators of these crimes to account in

domestic proceedings even if the acts did not take place within its borders by one of its nationals or against one of its nationals.

PHR has gathered forensic evidence across 25 villages, including Chut Pyin, affected by the violence in Rakhine state in August 2017 to contribute to independent, impartial, and effective investigations that will establish responsibility for the violence and to bring those responsible to justice, whether before the ICC or another court or justice mechanism.

The following recommendations are directed toward Myanmar to acknowledge and redress its human rights violations; to the United Nations Security Council to pressure for a referral to the ICC or the creation of an adequate accountability mechanism; and to other governments to acknowledge and address these violations within their spheres of influence.

Recommendations

"We need safety and security the way [other citizens] are protected. Without safety and security, we cannot go back... We need to be recognized as Rohingyas."
Sultan Ahmed, 19-year-old man (Profile 9)

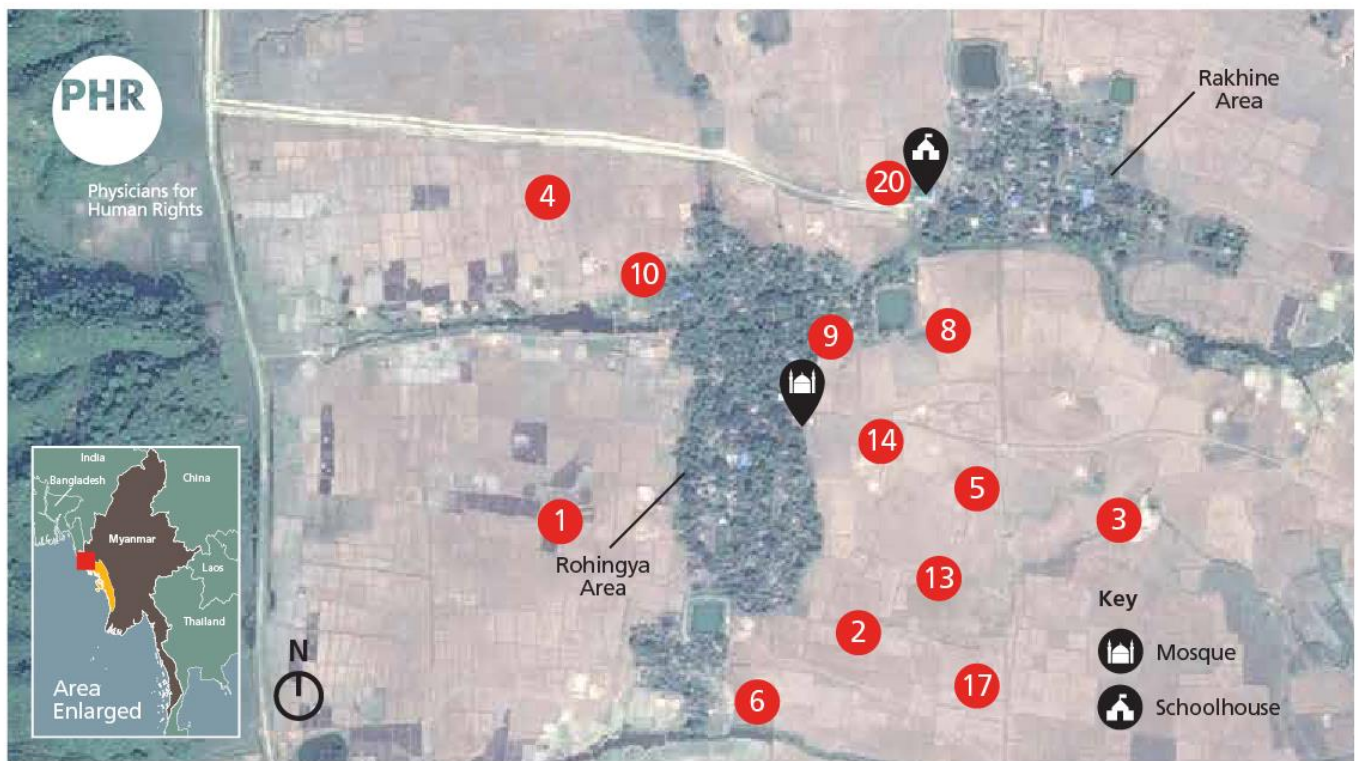
To the Government of Myanmar:

- Cease human rights violations and crimes against individuals and communities in Rakhine state and throughout Myanmar;
- Investigate and prosecute human rights violations in accordance with human rights law, as well as provide victims effective redress and reparation;
- Secure adequate safeguards against discrimination of ethnic minorities, including reforming all discriminatory laws and policies;
- Grant immediate unrestricted access to United Nations agencies, officials, and international humanitarian and human rights organizations to provide essential services and conduct investigations into alleged human rights violations in Myanmar, especially in Rakhine state;
- Secure guarantees of security and sustainable conditions for safe, dignified, and voluntary return for Rohingya refugees in accordance with protections under international law before any repatriation measure is implemented;
- Guarantee that any repatriation measure is overseen by full international human rights monitoring, based within Rakhine state and with full and unfettered access.

To the UN Security Council and UN Member States:

- Call on Myanmar to immediately cease attacks against civilians, investigate and prosecute crimes and other human rights violations against ethnic minorities, and provide victims of human rights violations access to effective redress;
- Demand unfettered access to Rakhine state for independent monitors, international human rights organizations, journalists, aid agencies, and other international observers, notably the Independent International Fact-Finding Mission which is presenting its final report to the UN Human Rights Council in September 2018;
- Ensure that the Bangladesh-Myanmar agreement on Rohingya repatriation is not implemented without actionable guarantees and sustainable conditions for safe, dignified, and voluntary return for the Rohingya, and accountability for those responsible for crimes and serious abuses against them;

- Pressure Myanmar to adopt adequate safeguards against ethnic discrimination, including those related to race and religion, population control, housing or religious buildings, marriage, and voting, among others;
- Impose bilateral and multilateral sanctions, including arms embargoes against the Myanmar military and targeted sanctions against individuals responsible for crimes and serious abuses;
- Call and/or vote for the UN Security Council to refer the situation of Myanmar to the International Criminal Court;
- Exercise universal jurisdiction or support other credible justice initiatives and independent investigations to hold perpetrators accountable, including efforts by civil society organizations and the Independent International Fact-Finding Mission on Myanmar established by Human Rights Council resolution 34/22;
- Contribute financial support to the Joint Response Plan for the Rohingya Humanitarian Crisis launched in Geneva in March 2018 to meet the \$951 million funding appeal;
- Ensure that the Intergovernmental Human Rights Commission of the Association of Southeast Asian Nations uses its influence to protect human rights in Myanmar.



Chut Pyin Case Profiles Map

This map shows where 13 of the 22 injured Rohingya survivors interviewed by Physicians for Human Rights indicated that they were injured and/or hid as the attack unfolded.

The numbers on this map refer to the case profiles that follow.

- | | | | |
|------------------|-----------------|--------------------|-------------------|
| 1 Laila Baegum | 5 Mohammed Isaq | 9 Sultan Ahmed | 14 Abaeda Khathu |
| 2 Shofiqul Islam | 6 Nur Asha | 10 Rahama Bi Bi | 17 Mohammed Yasin |
| 3 Anwar Sadak | 8 Sayed Alom | 13 Ayaesha Siddiqa | 20 Kismath Fatima |
| 4 Rabia Basri | | | |

Case Profiles

Below are the testimonies and forensic examinations of 22 survivors of the Chut Pyin massacre in August 2017 in Myanmar. These survivors were examined by Physicians for Human Rights (PHR) in Thangkali refugee camp in Bangladesh in December 2017 and February 2018.

Profile 1: Laila Baegum, 12-year-old girl⁸⁹

"It hurt so much. I had so much bleeding and the place was flooded with blood."

Laila Baegum was in a home with eight other people, including two siblings who survived the massacre (Profiles 2 and 3) when she heard shouting and gunshots. Laila looked through cracks in the wall of her home and saw Myanmar security forces and Rakhine Buddhist civilians entering the village, and then shooting into homes and setting them on fire.

When the house they were in was set on fire, Laila and her family tried to escape by running toward the fields, but they were all shot as they fled. When Laila reached a rice field, she felt a sharp pain in her left lower leg and fell to the ground. Laila then felt another sharp pain in her right upper leg and, looking down, she saw that a bullet struck her in the inner side of her leg.

Laila reported that she saw 10 to 15 other villagers on the ground around her. She also reported that the Myanmar military slit her older brother's throat. Eventually, neighbors came and carried her to a neighboring village, where she used garlic (known as a local remedy) topically and a bandage to cover the wound. In this village, Laila was reunited with her surviving grandmother and two siblings, and they were then taken to Bangladesh, where Laila received medical care at a hospital.

PHR Medical Evaluation

The following physical findings are highly consistent with Laila's testimony.

The wound on Laila's right leg is typical of a graze wound from a bullet. Her right posterior thigh has a 9 cm x 3 cm well-healed oval scar with irregular borders and a hypertrophied center along the midline of the long axis, indicating significant tissue disruption and initial poor wound healing, likely due to delays in receiving adequate medical care.

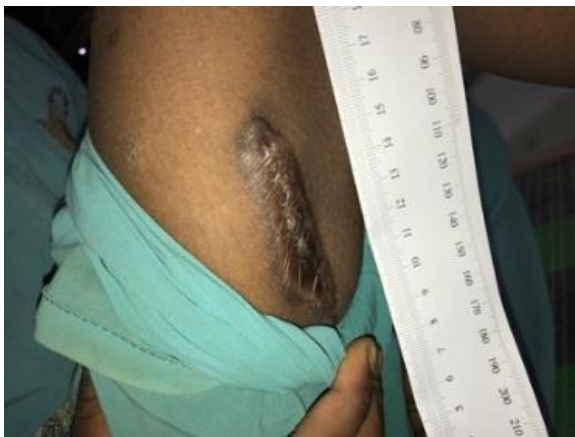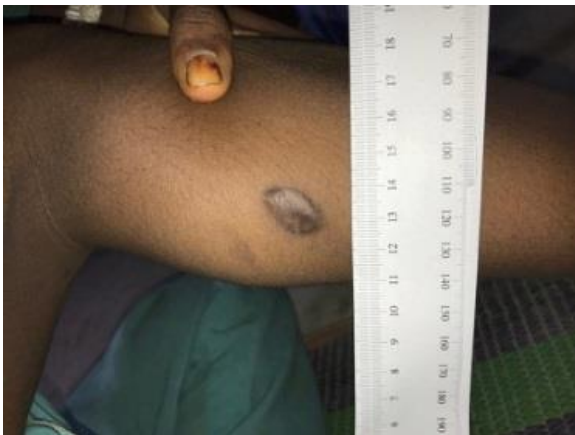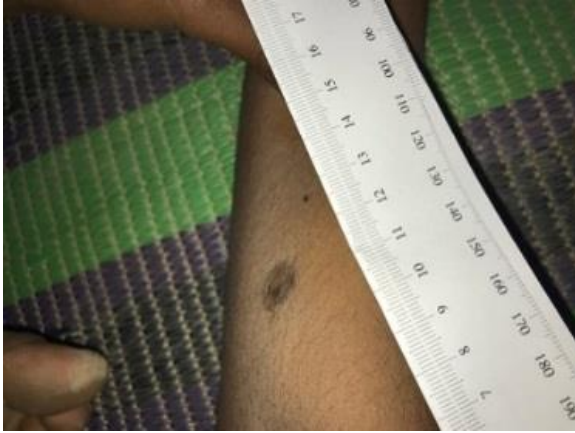The two scars on Laila's left leg are typical of gunshot entry and exit wounds. The smaller wound on her lateral calf, a 0.5 cm x 1 cm lesion 3 cm distal to the knee, is typical of an entry wound. This scar is uniform and well healed at the borders and margins, which is expected from a projectile entry wound.

The larger scar, a 2 cm x 1 cm oval scar on the medial/posterior aspect of her calf, is well healed, with irregular margins and a small area of hypopigmentation (1 cm x 0.5 cm), which is typical of a projectile exit wound. The hypopigmentation in the central area of the lesion is likely indicative of significant tissue disruption from the exit of the bullet through the skin.

Laila can walk without assistance, but still has moderate pain in her left leg.

Images taken by PHR's clinical team below show injuries consistent with a bullet entry wound (top) and exit wound (center) on Laila Baegum's left leg, and a graze wound on her right leg (bottom).

Photos: Physicians for Human Rights



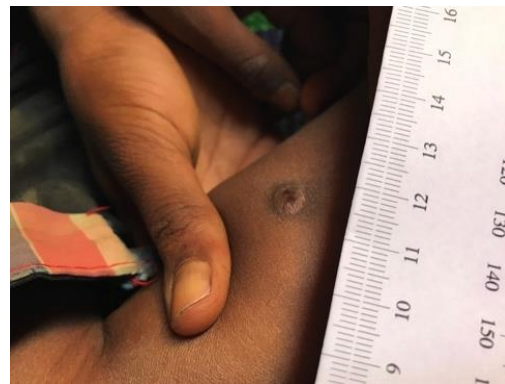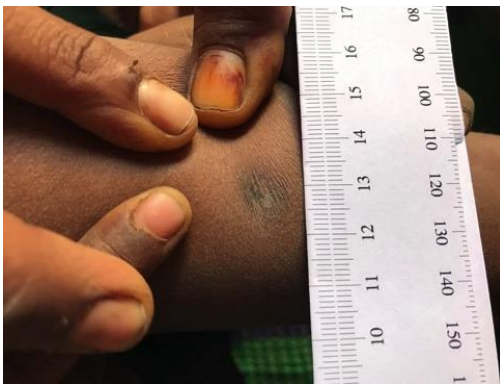Profile 2: Shofiquil Islam, 5-year-old boy⁹⁰

When Myanmar security forces arrived in Chut Pyin, Shofiquil Islam ran out of his home with his family, including two siblings who also survived the massacre (Profiles 1 and 3). As he was running, he was shot in the left lower leg. When he was rescued, he needed to be carried and could not walk. He was reunited with his siblings and grandmother in a neighboring village. Shofiquil's gunshot wound was treated at a hospital in Bangladesh.

PHR Medical Evaluation

PHR's findings are highly consistent with Shofiquil's testimony of being shot from the left side while running.

The two scars on the lower left leg are typical of a projectile bullet injury with lateral entry and medial exit wounds. On the lateral aspect of the calf, approximately halfway between the knee and ankle, a 1 cm circular scar is present, with a clear regular margin typical of an entry wound. On the medial aspect of the calf, a 1 cm x 1.5 cm scar is present, oval in shape and with moderately defined margins. There are no bone deformities on palpation and therefore there is no evidence that the bullet damaged the bone. Shofiquil is able to ambulate without difficulty.



Images taken during PHR's forensic medical examination show injuries consistent with a bullet entry wound (left) and exit wound (right) on Shofiquil Islam's left leg.

Photos: Physicians for Human Rights

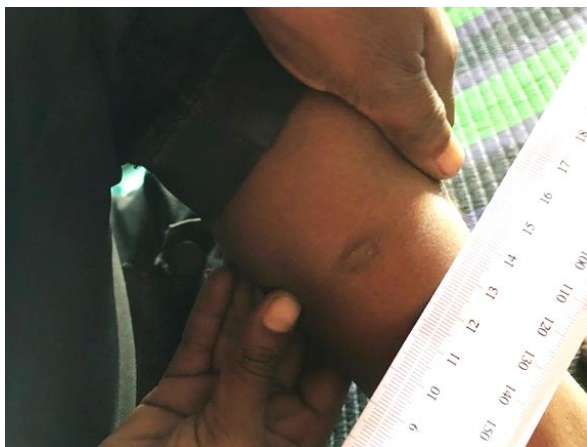Profile 3: Anwar Sadak, 7-year-old boy ⁹¹

When the attack began, Anwar Sadak ran out of his home with his family, including two siblings who survived the massacre (Profiles 1 and 2). He escaped with his mother by running to the nearby fields. His mother was shot in the stomach and she fell to the ground. As he got closer to her, Anwar was shot and also fell down. Anwar lay in the fields bleeding for several hours until neighbors could carry him to a nearby village, where a doctor examined him.

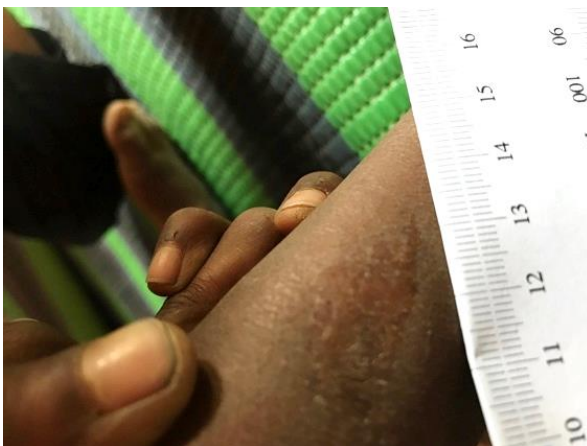PHR Medical Evaluation

Anwar's right leg has scars that are highly consistent with his testimony of having been shot.

The two scars are typical of gunshot injuries, with lateral entry and medial exit wounds, missing the bones of the lower leg. On the medial aspect of the calf, approximately halfway between the knee and ankle, a 0.5 cm x 1 cm oval scar is present, with a clear regular margin and flat surface, which is typical of an entry wound. On the lateral aspect of the calf, a 2 cm x 1 cm area of scarring is present, oval in shape and hyperpigmented (darker) in the center – typical of an exit wound. The margins of this scar are poorly defined. No bone deformities are appreciated on palpation. Both scars are well healed and Anwar is able to walk without difficulty, indicating that the bullet did not strike bone or any major neurovascular structures.



Images taken by PHR's clinical team show injuries consistent with a bullet entry wound (top) and exit wound (bottom) on Anwar Sadak's right leg. Photos: Physicians for Human Rights



"I lost my family and my life."

Rabia Basri was at home with 14 relatives when they heard gunfire and tried to run to the surrounding rice fields. Five of them were shot dead while trying to escape. Rabia fell when she was struck in the left leg and right arm. She reported being in and out of consciousness while she lay bleeding. She recalled pretending to be dead when six or seven Myanmar security forces and Rakhine Buddhist villagers approached her. They stole her valuables and left her in the field, where she stayed well into the night until neighbors carried her to a nearby village. Two days later, Rabia left for Bangladesh, where she underwent surgery on her leg with orthopedic external fixation.

PHR Medical Evaluation

The physical findings are highly consistent with Rabia's report of being shot while running.

Over her arm, a small round lesion on the antecubital fossa (interior crease of the elbow) connected to a 6 cm linear defect with suture scars on either side is highly consistent with a gunshot injury from a low velocity bullet that did not pass completely through the arm and which resulted in extraction of a bullet and suturing (surgical closing of the wound) afterwards.

The lower leg displays a group of scars consistent with a single bullet entry wound, causing fracture to the tibia and fibula, and subsequent surgical repair. A single 1 cm x 2 cm oval scar is apparent on the anterior/medial aspect of the tibia (large bone of the lower leg), approximately 8 cm below the patella (kneecap), with some blurring of the margin inferiorly, likely representing the entry wound of the projectile. Irregularity of the bone structure of both the tibia and fibula (large and small bones of the lower leg, respectively) is appreciable on palpitation of the scar. The lower left leg has a longitudinal surgical lesion with punctate suture scars on either side. The gastrocnemius and soleus muscles (calf muscles) of the left leg appear grossly atrophied when compared with those of the right leg.

Rabia can hold her knee at 120°, but cannot flex her knee more than 30° in any direction. The resultant atrophy and inability to walk likely reflects significant injury to the bones and the neurovasculature of the leg – most likely due to initial injury and subsequent underuse of her calf muscle. The limited range of motion of the knee joint is most likely an indirect consequence of the initial injury due to lack of access to post-operative physical therapy. Rabia now is unable to walk or bear weight without crutches; when transferring from a chair to the floor, she cannot use her left leg at all.

Profile 5: Mohammed Isaq, 17-year-old boy⁹³

"I will not go back there without our rights. I would rather die here."

As Mohammed Isaq walked home from afternoon prayers, he saw the village being surrounded by Myanmar security forces and Buddhist Rakhine villagers. He then heard gunshots and security forces ordering people to come out of their homes. He sought shelter in a house, where he was then struck by a projectile shot from outside. The house was then set on fire and Mohammed came out dragging his leg. He then hid by a pond until 4 a.m., when his father rescued him and took him to a neighboring village. Mohammed also said the Myanmar military shot people and Rakhine Buddhist villagers then stepped on those injured and slit their throats. He also reported the attackers set dead bodies on fire.

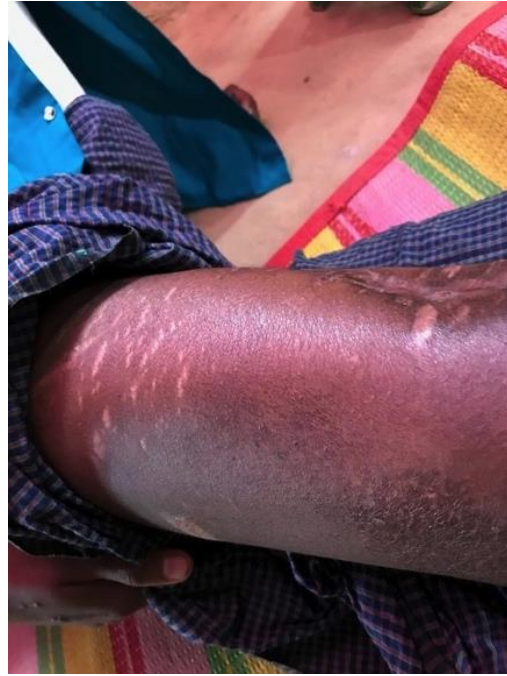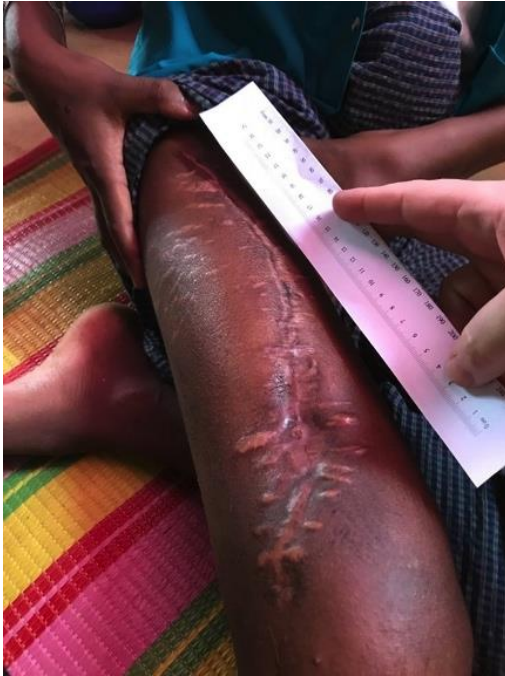After remaining in a neighboring village for a week, Mohammed then began a 12-day journey to Bangladesh, where he was hospitalized for five months and underwent multiple surgeries with rods and screws in his leg. Six months later, he still could not bear weight on that leg and required crutches to walk.

PHR Medical Evaluation

The lesions present on Mohammed's right leg are highly consistent with an explosive blast injury, with multiple shrapnel scars and a long linear surgical scar to extract fragments and surgically repair his femur (large bone of the upper leg) with internal fixation.

The right anterior thigh displays numerous linear scars on the lateral aspect of the mid-thigh, measuring 2 cm to 5 cm in length and slightly raised, indicating multiple blast fragment scars typical of a grenade injury. A single irregular 1.5 cm x 1 cm scar is present on the medial aspect of the thigh just superior to the patella (above the kneecap), with an irregular border, consistent with an exit wound from a fragment.

This leg also has a vertical linear surgical scar that starts on the anterior thigh near the level of the iliac crest (highest part of the sacrum, also known as the "hipbone") and extends down the anterior thigh ending inferolateral to (below and to the side of) the patella. This scar is approximately 40 cm in length, varying in width from 0.5 cm and relatively clean approximation (wound closure) to a 4 cm wider region near the patella that is hypertrophied (enlarged) and poorly approximated. The surgical defect is consistent with internal fixation of the femur bone and the removal of shrapnel in certain places. A second line of sutures is present along part of the original surgical scar, indicating that this likely did not heal and required a second effort to close. Mohammed's continued pain, inability to bear weight, and reliance on crutches suggest that he suffered from significant bony and neurovascular injury that has not healed well, despite surgery.



A forensic medical examination by PHR of Mohammed Isaq's right leg revealed lesions highly consistent with an explosive blast injury, with multiple shrapnel scars and a long linear surgical scar to extract fragments and surgically repair his femur.

Photos: Physicians for Human Rights

"I will never forget what happened to me. I am always thinking about it."

Nur Asha said that on the day of the Chut Pyin attack, four Myanmar security forces surrounded her house and ordered her to come out. When she came out with her four-month-old daughter and two-year-old son, they burned Nur's house down,

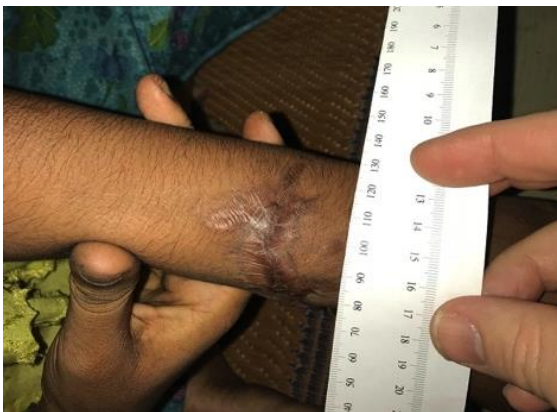Nur managed to flee by running, but she and her son were shot when they reached the rice field. The bullet killed the child and then entered Nur's left wrist. After she was shot, she said military came and kicked her three times to check whether she was dead. Nur lay in the rice field and estimated that she was surrounded by roughly 100 other women doing the same. She said her sister-in-law, lying nearby, refused to surrender her baby boy when the military tried to wrest him from her; they shot the mother dead, and, when the baby fell from her hands, they shot the baby as well. "The bullet entered the head and it didn't exit." Nur said scores of people were killed in the rice fields around her. "People died like small fish in a dried pond.... I myself alone, had to cross 25 dead bodies." She made it to the next village and then walked approximately 11 days to reach Bangladesh, where she underwent surgery on her wrist.

PHR Medical Evaluation

Nur's clinical exam is highly consistent with her report of a surgically treated low-velocity gunshot wound, such as one that would have been caused by a bullet travelling through her son before striking her.

An examination of her left hand shows a hyperpigmented and raised lesion extending from the radial side of the forearm to the dorsum of the wrist. The dimensions of the wound are approximately 8 cm long x 2.5 cm wide. It has jagged borders and areas of skin contraction, indicating that the scarring pattern was irregular, consistent with the injury being caused by a lower-speed projectile. Nur has a grossly decreased sensation of her first, second, and third digits (thumb, index, and middle fingers) from the palm to the proximal interphalangeal (middle finger) joints, which is typical of a radial nerve injury. She rests her hands with over-flexion of the fingers and has limited range of motion and pain with active movement of the fingers and wrist.

While PHR did not conduct a full psychological evaluation, Nur displays an affect consistent with the psychological effects of trauma, crying throughout the interview and alternating between reporting what happened when asked and staring blankly for extended periods of time.



PHR's forensic medical examination of Nur Asha's left hand found a lesion highly consistent with her report of having been struck in the wrist by a bullet that first killed one of her children.

Photo: Physicians for Human Rights

Profile 7: Somaiya Akter, 9-year-old girl⁹⁵

"If I have to go back, I will just die here."

Somaiya Akter was at home with her mother (Profile 19), brother, and father when they heard gunshots and saw smoke coming from many nearby homes. They ran out of their house when it, too, was set on fire, and Somaiya's father and brother were shot dead just 20 to 30 yards from their home. Somaiya was shot in the leg and could not continue running, so she stayed by the bodies of her father and brother.

Myanmar security forces took Somaiya's mother to one of the places where the military were gathering women. They hit her on her head and back with sticks, but she managed to escape and return to where her husband, daughter (Somaiya), and son were shot.

Both Somaiya and her mother then fled into the fields and later spent 10 days traveling to Bangladesh, where Somaiya had surgery on her leg, which had become infected. Six months later, Somaiya still had to walk with a stick and the wound had not healed properly.

PHR Medical Evaluation

The scars on Somaiya's leg are highly consistent with her and her mother's testimony.

Somaiya's right thigh has scars from bullet entry and exit lesions, and from surgical treatment. The mid-thigh reveals two bullet wounds: a 2 cm x 2 cm circular, well-healed entry wound on the posterolateral aspect (back) of the mid-thigh and an irregular 2 cm x 4 cm oval hypertrophied (enlarged) exit wound on the anteromedial aspect (front) of her thigh. Somaiya also has circular puckered wounds near the patella (kneecap) and at the superior aspect of the thigh, typical of surgical scars from an external fixator used to immobilize a leg after surgery.

Somaiya requires a cane/stick to walk and has significant pain when bearing weight on her leg. Six months after the incident, the exit wound has a slow drainage of purulent fluid and a red, inflamed appearance. She reports no fevers, but her leg appears to have a tissue or bone infection.

Profile 8: Sayed Alom, 21-year-old man⁹⁶

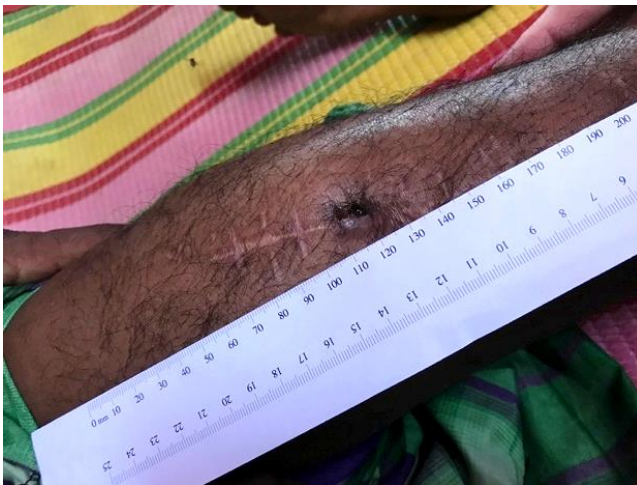“After being shot or cut, people were thrown into the fire of burning houses.”

Sayed Alom ran out of his home when he heard shooting and yelling, and ducked into a neighbor's home as gunfire began and he saw how many Myanmar security forces were in Chut Pyin. He was shot in the left lower leg and managed to hide in the nearby rice fields, where he reported being surrounded by 10 to 20 people, some shot and others with slit throats, as well a dead woman with a mutilated breast. He also said that his congenitally disabled uncle had been stabbed and killed by gunshot. Sayed lay in the field until his brother found him the next day and brought him to a nearby village. He was then carried to Bangladesh, which took 10 to 12 days. Once Sayed reached Cox's Bazar, he spent five months in the hospital for leg surgery.

PHR Medical Evaluation

The physical examination of Sayed's left leg reveals a single scar on the anterior tibia and surgical scars on the lower leg that are highly consistent with his report of a gunshot injury that was surgically repaired.

A single oval scar measuring 1 cm x 1.5 cm, typical of a bullet entry wound, is present on the anterior surface of the left lower leg, approximately 5 cm below the patella (kneecap). The left leg also shows evidence of surgical repair of the tibia (large bone of the lower leg), with a linear wound running the entire length of the lower leg from the patella to the ankle. There also are scars consistent with placement and subsequent removal of fixator screws along the anterior and lateral axes of the lower leg. Sayed reports that he requires a cane/stick to walk and has moderate, persistent pain.



PHR's forensic medical examination of Sayed Alom found an oval scar and a surgical scar on his left leg, which are highly consistent with his report of being shot as he ran. Sayed spent five months in a Bangladesh hospital for leg surgery, continues to have pain, and needs a cane to walk.

Photo: Physicians for Human Rights

“Parents were killed. Brothers and sisters were killed. Even small children were burned in the fire.”

On his way home from prayers on the day of the attack, Sultan Ahmed saw Myanmar security forces gathered inside and outside the village. Once home, he heard orders for everyone to leave their houses. As he tried to flee, Sultan was shot in the left ankle and right shoulder. He also said he was grazed on the head by two bullets.

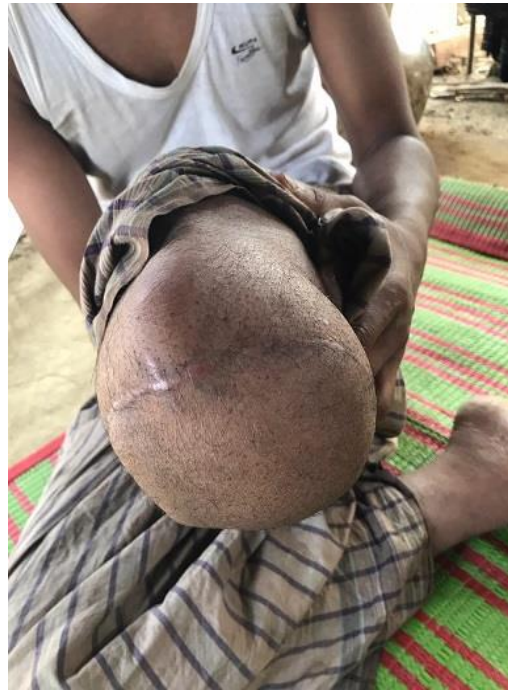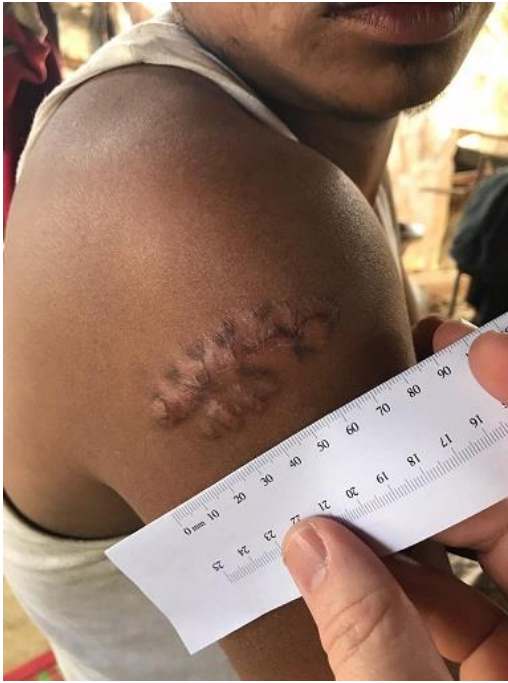Sultan was able to hide in a shallow pond near his house for many hours until neighbors rescued him. During this time, he saw dozens of women and girls being taken inside the school, where many were raped and killed. He heard them crying “Oh, father, oh, mother, come and save us!” and saw a woman with mutilated breasts. Sultan also reported overhearing orders that all Rohingya men and boys be killed; those who did not die from bullet wounds had their throats slit. While hiding, he said he saw children being thrown into a fire and dozens of dead bodies.

After 10 hours of hiding, neighbors carried Sultan to a nearby village, where he spent seven days before traveling to Bangladesh. Once in Bangladesh, he was hospitalized for 14 days. Doctors amputated his left lower leg and surgically removed the bullet that was lodged in his left shoulder. Sultan added that neighbors told him that his father was taken and killed, but he does not know any further details.

PHR Medical Evaluation

Sultan’s injuries are highly consistent with his testimony of having sustained a head wound, multiple gunshot injuries, and the amputation of his left leg.

He has a 7 cm x 4 cm oval scar on his right deltoid (shoulder) area, oriented in an anterior/posterior direction with hypertrophied (enlarged) and irregular margins and hyperpigmentation. The scar has suture sites on the lateral aspects, consistent with surgical removal of the projectile at the site of entry, with no bullet exit wound. The wound appears poorly healed, likely secondary to delayed treatment. Sultan also has a 0.5 cm x 1 cm linear scalp scar with broad margins to the left side of the head consistent with his report of being struck in the head. The cause of the head injury is unclear and therefore the cause cannot be established. The amputation of his left leg below the knee is consistent with Sultan’s report of being shot in the lower leg, and then being unable to walk because of significant injury to the neurovasculature or bones of the leg. The surgical scar is closed and well approximated (cleanly healed); the entire area is pain free. He requires crutches to walk on his remaining leg.



PHR's forensic medical examination of Sultan Ahmed found a poorly healed scar on Sultan's right arm and evidence of the amputation of his lower right leg, both highly consistent with his report of having been shot during the attack on Chut Pyin and requiring a subsequent amputation.

Photos: Physicians for Human Rights

Profile 10: Rahama Bi Bi, 18-year-old woman⁹⁸

“They yelled as they shot at us, ‘You are Bengali, you have no place here.’”

Rahama Bi Bi was at home with five relatives when Myanmar security forces and Rakhine Buddhist civilians came into the village, kicking doors and firing guns into houses as they shouted, “You are Bengali, you have no place here.” Rahama and her family ran toward the rice fields, where she was shot in the left upper arm and fell to the ground. She lay there until sunset.

During this time in the rice fields, Rahama saw several women raped and killed; she also witnessed boys having their throats slashed. After the Myanmar security forces left the village in the evening, neighbors took Rahama and other survivors to a nearby village. Two days later, she and her family traveled to Bangladesh, where a doctor treated the infected gunshot wound on her arm.

PHR Medical Evaluation

The physical findings of Rahama’s examination are highly consistent with her report of gunshot injury.

She has two scars on her left upper arm. On the lateral (outer) side, approximately midway between the elbow and shoulder, there is a 0.5 cm circular, well-healed scar with a well-defined margin, typical of an entry wound. On the medial (inside) aspect of the arm, roughly 4 cm distal (below) to the first wound, there is an oval 1 cm x 3 cm scar with a moderately defined margin and somewhat irregular texture, typical of an exit wound. The irregular texture also is consistent with Rahama’s description of suffering from a local infection that is now healed. There is no deformity of the humerus (long bone of the upper arm) or localized pain on palpation.

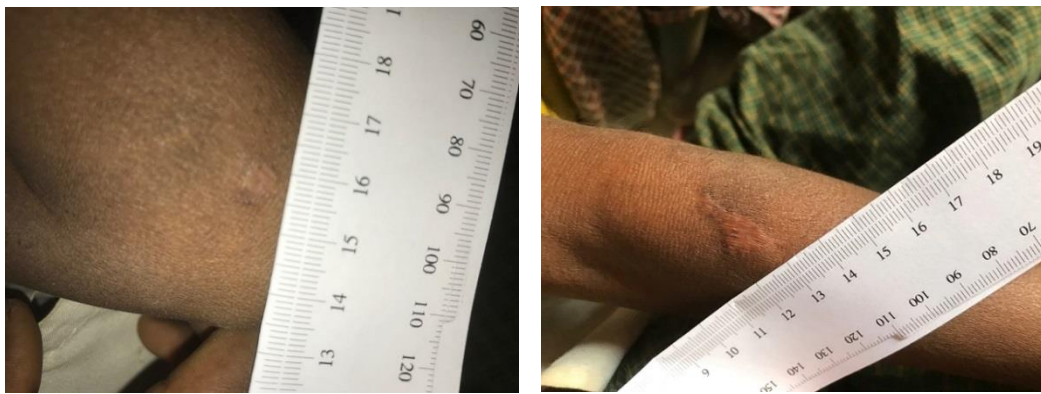
Profile 11: Rahamed Ullah, 10-year-old boy ⁹⁹

Rahamed Ullah was home with nine relatives when they heard gunfire and ran from their home toward the fields. As he was running, Rahamed was shot in the arm and fell down. His older brother picked him up and carried him to a nearby village. The family reunited there and traveled to Bangladesh over a period of a month. Rahamed was hospitalized for two days but did not undergo surgery.

PHR Medical Evaluation

The physical findings in this case are highly consistent with the gunshot injury described by Rahamed, with entry at the medial (inside) of the forearm and exit on the lateral (top/outside) aspect.

On the medial aspect of Rahamed's forearm, approximately 6 cm distal (below) to the antecubital fossa (interior crease of the elbow), there is a 0.5 cm circular scar that has a faint but discernable margin and flat surface that is typical of a bullet entry wound. On the lateral (top) aspect of the arm, on the antebrachial area (forearm) approximately 4 cm distal to the elbow, there is a teardrop-shaped scar with an irregular and mildly raised superior margin, typical of a bullet exit wound. The irregular and larger appearance of the exit wound suggests a more complicated healing pattern, possibly secondary to infection or delay in closure of the wound.



10-year-old Rahamed Ullah was shot in the arm as his family fled across the fields during the Chut Pyin attack. His brother carried him to a nearby village, where his family reassembled before starting the trek to Bangladesh. PHR's forensic medical examination of Rahamed's arm revealed scars consistent with a bullet entry wound (left) and exit wound (right).

Photos: Physicians for Human Rights

"They thought I was dead so they did not rape me."

Jahan Ara was in her house with five other relatives when they heard gunfire. Her uncle was struck in the head by a bullet while inside the house; the rest of the family escaped toward the fields. As they were running, Jahan's cousin was shot and fell to the ground. Jahan was struck by a bullet in her left shoulder and fell.

Jahan reports that she was in and out of consciousness while she lay in the field, but remembers that a group of three Rakhine Buddhist civilians and one soldier walked by her. They kicked her and she pretended to be dead, so they took her jewelry and left. Jahan said that more than a dozen dead bodies surrounded her in the fields. After the massacre, her grandmother and others carried her to a nearby village, where they stayed for roughly six days. They then went to Bangladesh, where Jahan was hospitalized for more than a month.

PHR Medical Evaluation

Jahan's physical examination is highly consistent with her report of gunshot injury with entry to the left deltoid (shoulder muscle) and damage to the soft tissues of the shoulder and the clavicle (collarbone) – and, possibly, the scapula (shoulder blade) – before exit.

On her anterolateral (front-side) deltoid area, Jahan has a 2 cm x 3 cm scar, which is teardrop in shape and has a poorly differentiated margin. There is an appreciable deformity in the mid-clavicle, but the scapula appears intact by palpation. Jahan has a second scar on her left scapular area, triangular in shape and approximately 3 cm x 4 cm, with poorly differentiated margins and hypertrophy (enlargement) near the inferior aspect (bottom) of the wound. Based on the physical evaluation, the bullet likely entered her shoulder on the side, hit and broke her clavicle, bending the curve of the bullet, which then angled out of her upper back near the scapula.

Jahan has limited range of motion in her shoulder. She is able to elevate her arm 45° above horizontal in the anterior plane (forward) and only 30° above horizontal in the lateral plane (side). Her report of improvement after surgery, subsequent deterioration in mobility and range of motion, and persistent pain reflect a lack of access to post-operative care and physical therapy.

Profile 13: Ayaesha Siddiqa, 13-year-old girl¹⁰¹

"I cannot go [back] there, I will surely die."

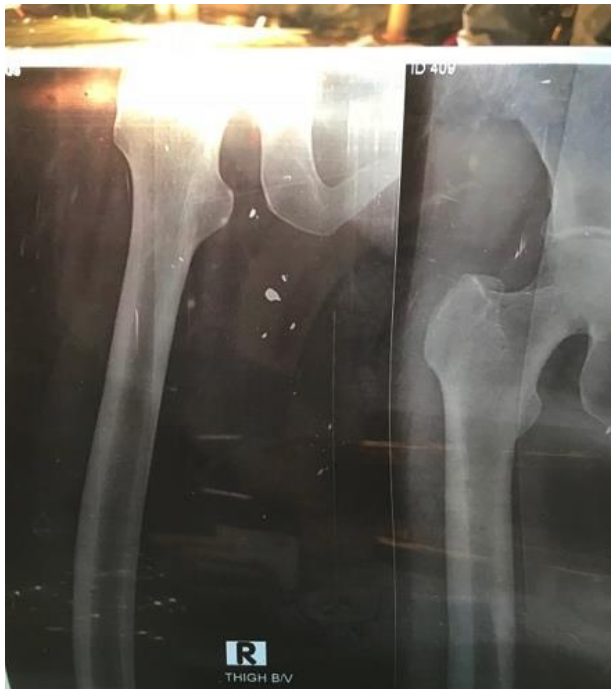Ayaesha Siddiqa was at home with six relatives in the southern part of Chut Pyin when they heard gunshots and saw houses on fire. They all ran west toward the rice fields, where a bullet struck Ayaesha in her right hip. She hid in the fields until the evening, when she was found and carried to a nearby village. She stayed there for a week and then traveled for two weeks to Bangladesh, where doctors removed bullet fragments from her hip. Her mother survived (Profile 14), but her brother, sister-in-law, father, and nephew were shot dead.

PHR Medical Evaluation

Although the PHR team did not conduct a full physical examination, they reviewed Ayaesha's x-rays, which are highly consistent with her testimony of being shot in the lateral hip (side of the hip) while fleeing.

The x-rays reveal multiple irregular-shaped radiopaque foreign bodies (solid, visible objects) in the right posterior hip and thigh. The largest of the fragments is 0.5 cm, teardrop-shaped and located in the soft tissue of the upper leg approximately 4 cm below the ischial ramus (hip bone). All other fragments seen are lodged above this location. A second x-ray of the left upper leg also reveals at least seven fragments spread throughout the tissue medial to the inferior pubic ramus (in the middle of and below the pubic bone). One isolated fragment is seen at the level of the greater trochanter (top of the femur, the large bone in the upper leg), appearing posterior to the bony structures of the joint.

Taken together, these findings are consistent with shrapnel from a bullet that entered the lateral right hip and shattered/deflected on impact within the pelvis. This left in the right pelvis and upper thigh multiple deep bullet fragments that cannot be removed. The x-rays do not show broken bones and Ayaesha is able to walk without assistance, but with pain.



PHR's forensic medical review of Ayaesha Siddiqa's x-rays revealed multiple foreign bodies in the right hip and thigh consistent with a bullet entering her hip and shattering on impact within her pelvis.

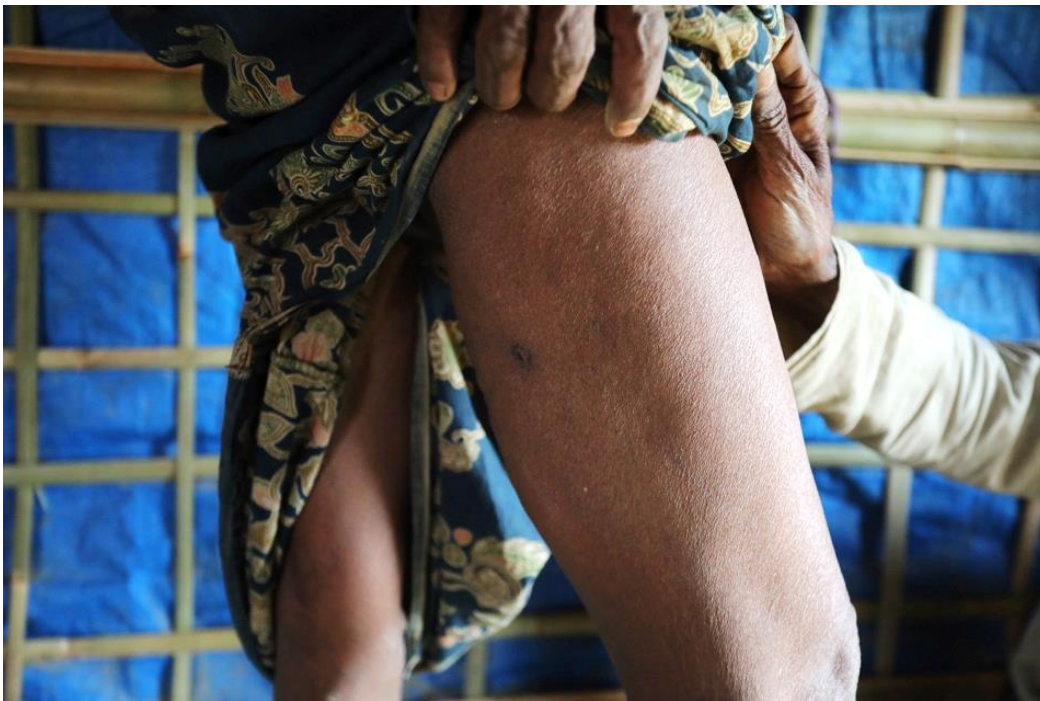Photo: Physicians for Human Rights

"I will never go [back] there. The killers are there."

Abaeda Khatu was in her home with six relatives when she heard gunshots and saw houses on fire. As the family ran to the rice fields, they heard women screaming inside several houses; Abaeda believes they were being raped. Abaeda and her relatives were shot as they were running toward the fields to hide; her husband, son, daughter-in-law, and grandson were all killed. Abaeda reported that as she ran, she felt a pain in her upper right leg and fell down. She lay in the fields for hours until others came to carry her to a neighboring village, where she stayed for seven days. Abaeda was carried on a 14-day journey to Bangladesh. Once there, she was taken to a hospital for treatment.

PHR Medical Evaluation

The scar on Abaeda's leg is highly consistent with her report of being shot from behind on her upper right leg while fleeing, and indicates a single gunshot entry wound with no exit wound. She has one oval scar measuring 1 cm x 1.5 cm on her right posterior thigh, located approximately 6 cm below the level of the greater trochanter (top of the femur, the large bone in the upper leg), just below the buttocks. No bony deformities are appreciated underneath the scar and no other scar is apparent on the upper leg. There is no exit wound or suture marks, indicating that the bullet either lodged in Abaeda's leg or became dislodged and fell out. Abaeda reports that she is able to walk without pain.



PHR's forensic medical examination of 50-year-old Abaeda Khatu found a scar on her upper right leg which is highly consistent with her report of being shot from behind while fleeing Chut Pyin.

Photos: Physicians for Human Rights

"I will be killed there. I would rather be shot or stabbed to death here."

Anayath Korim was in his home just outside the village of Chut Pyin when he heard gunshots coming from the village, and several children ran into his house for shelter. As nine people hid inside Anayath's home, a large explosion occurred and he lost consciousness. He awoke a short time later as neighbors were carrying him to a neighboring village.

PHR Medical Evaluation

The physical findings are highly consistent with Anayath's testimony of sustaining a significant blast injury which resulted in burns to his leg.

The entire lateral aspect (side) of the right leg, from the groin to the ankle, is covered with extensive burn scars. These areas appear mottled with areas of hyper- and hypopigmentation (mixed discoloration), irregular texture, lack of hair, and contractures typical of a full-thickness burn injury. There are some areas that appear to have undergone surgical grafting of skin from other non-affected areas to replace some of the missing skin. This type of extensive, full thickness burn suggests a significant blast injury that resulted in Anayath becoming unconscious and unable to remove himself from the burning home quickly enough. He suffers from permanent scarring, pain, and difficulty moving his joints, and he walks with a limp.

Profile 16: Mohammed Yusuf, 5-year-old boy¹⁰⁴

Mohammed Yusuf and his family live in a neighboring village that is roughly a 10-min walk from Chut Pyin. He and his older brother were playing near Chut Pyin when he heard gunfire and explosions close to him, followed by a sudden pain in his right eye. His brother carried him home to their mother, who saw that Mohammed's eye was covered with blood. She cleaned him up, but Mohammed said his head still hurt. Over the next four days, Mohammed did not get up and ate very little. Since then, he has not been able to see out of his right eye and cannot hear out of his right ear. Concerned that their village would be attacked, Mohammed's family decided to walk to Bangladesh, which took seven days. Once they arrived, Mohammed's mother took him to a hospital in Cox's Bazar.

PHR Medical Evaluation

The physical examination findings of blindness in Mohammed's right eye and hearing loss in his right ear are consistent with his testimony of exposure to explosions and blast trauma.

Mohammed's right eye exhibits a loss of the border between the iris and pupil, which are both grey in color and difficult to distinguish. He is completely blind in the right eye and cannot see light/dark or any colors. The pupil is not reactive to light. There is a single linear deformity that is oriented vertically from the 1 o'clock location of the iris through the pupil to the 5 o'clock position of the iris. Eye movement is intact. No injury is apparent to the soft tissues around the eye. These findings are highly consistent with an ocular injury with damage to the pupil. This is consistent with the effects on the eye of small foreign bodies that can be blown into the air during blasts from grenades and other explosive military weapons.

The right ear does not exhibit any external signs of trauma. No otoscope was available for this evaluation, so visualization of the inner ear and tympanic membrane was not possible. Two medical exams were administered to test for hearing loss. The Weber hearing tuning fork sound is heard equally loudly in both ears when hearing is normal; however, Mohammed's test lateralized to the right ear, while the Rinne hearing test found that Mohammed heard the tuning fork better over air in the left ear (normal) and better in the bone in the right ear (abnormal). In sum, these findings detected a conductive hearing loss in the right ear, likely secondary to blast wave trauma to the middle ear or cochlea. Post-traumatic conductive hearing loss is highly consistent with Mohammed's testimony of blast trauma.

Profile 17: Mohammed Yasin, 60-year-old man¹⁰⁵

Mohammed Yasin had just returned home from afternoon prayers when the attack began. He ran out of his house with his two nephews, intending to escape into the fields, but the gunfire was so intense that he had to duck into a neighbor's home, and then move from house to house. Mohammed reported seeing Myanmar security forces and Buddhist Rakhine civilians shooting into homes, and estimates that he witnessed more than a dozen people killed. As Mohammed attempted to make it to the fields, he was shot in his right leg, but continued running until he was shot in his left foot and fell to the ground. Mohammed managed to crawl to a nearby village, and he believes that the bullet lodged in his left foot fell out during this time.

Mohammed sought medical care in this village, but doctors had been instructed by the Myanmar military to report anyone who arrived wounded. One doctor told Mohammed that between 50 and 60 people with gunshot wounds had already arrived in the village and had been detained by the military, so he was certain that Myanmar security forces would return to see if there were additional wounded Chut Pyin villagers seeking assistance. Mohammed was carried to Bangladesh over 12 days and taken to a hospital, where his wounds were treated. Mohammed's two nephews survived the massacre uninjured.

PHR Medical Evaluation

Mohammed's wounds are highly consistent with his testimony.

He has two scars on his right upper leg, both located above the patella (kneecap). The initial scar, typical of a bullet entry wound, is a 0.5 cm x 1 cm oval scar with well-marginated borders located on the lateral aspect (side) of the thigh, approximately 5 cm above the patella. The second scar is linear and measures 5 cm x 0.5 cm, beginning approximately 4 cm medial to the first one and located on the same horizontal axis. This gunshot likely traveled from Mohammed's right side through to the middle of the thigh before exiting, and the wound appears typical of a projectile exit wound that travels through the superficial dermis (top layers of the skin) before exiting, causing an extended area of skin trauma.

Mohammed's left foot has a single round 1 cm scar located over the cuboid bone in the lateral mid-foot area, with a distinct margin. There is mild bony deformity under the skin and moderate pain to palpation. The physical findings in this case are highly consistent with Mohammed's report of sustaining separate gunshot injuries to the right leg and left foot. The injury to the right leg appears to have been from a projectile that entered laterally and exited medially, while the single scar on the left foot indicates a single point of relatively low-velocity entry, consistent with Mohammed's report of the bullet falling out shortly after impact.

“My husband and [children] were shot while they were fleeing. My husband was carrying the boy on his back and holding the girl with his hand.... None of them survived.”

Umma Salama described that, on previous occasions, Myanmar security forces had beat her children when they were fishing at a nearby river. On the day of the massacre, Umma was at home with eight relatives, including her four children: a five-month-old boy, a four-year-old boy, a six-year-old boy, and a nine-year-old girl. Myanmar security forces surrounded her home and ordered her family to come out. She opened the door and when the assailants came in, they hit her on the back of the head with a gun. They then took her away and tied her to a tree, shouting “Don’t cry.... If you cry, you will be killed.” As she was tied to the tree, Umma witnessed several other villagers shot dead, and a bullet grazed her leg.

While she was tied up, Umma saw Myanmar security forces setting fire to her house, and her husband, brother-in-law, daughter, and son trying to run away. Umma witnessed these four family members shot dead. Once the military left, hours later, Umma’s mother-in-law untied her from the tree. They hid in the forest for hours and then went to a neighboring village, where she met others from Chut Pyin. A week later, they began walking to Bangladesh out of fear that the Myanmar military would return. The trip included three days in the forest, two days walking by a river, and then taking a boat to cross the river. Umma described that her wound was bleeding and swollen, so she spent two days in the hospital when she arrived in Bangladesh, possibly to address an infection due to the untreated wound on her leg.

PHR Medical Evaluation

Umma’s examination findings are highly consistent with the physical and psychological trauma described in her testimony.

On her medial right thigh, she has a well-healed, 2 cm x 2 cm hyperpigmented (darker) scar with irregular borders, which is consistent with her report of a graze wound from a bullet for which she did not receive immediate treatment. The large surface area and irregular borders suggest that the wound may have become infected because of the delays in care. Additionally, for most of the interview, Umma had a flat affect, with tears flowing down her face. She repeatedly pulled at a string on her shawl and made limited eye contact. This demeanor is highly consistent with the psychological effects of the trauma that she described.

Profile 19: Hala Banu, 35-year-old woman¹⁰⁷

“As they were beating me, my child fell down from my arms. When I tried to pick up the child, they kicked me at my forehead and I fell down again.”

Hala Banu was home with her husband and two of her five children when they heard gunfire and saw the military burning Chut Pyin homes. Although they saw Myanmar security forces shooting those fleeing, her husband thought it better to try to run away than to die inside their home. When they attempted to escape through the back of their house, however, Hala’s husband was shot in the shoulder and her six-year-old son was shot in the stomach. Hala reported that she could see her child’s organs exposed and believes that her husband died instantly. Hala’s nine-year-old daughter Somaiya (Profile 7) was shot in the leg and lay bleeding.

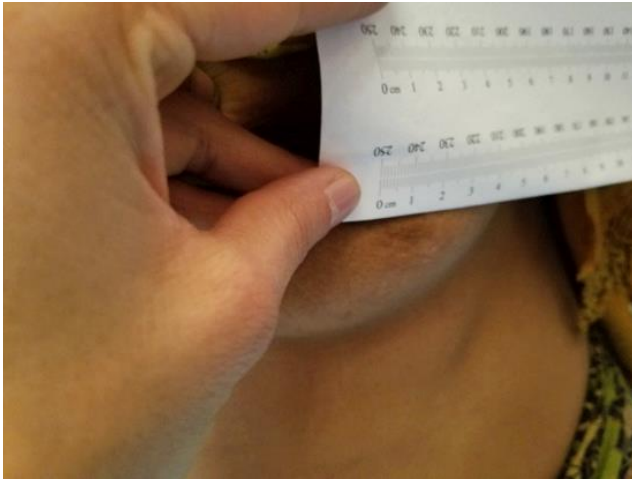A soldier tried taking Hala to the school where women and girls were held and many were raped, but she resisted, so he hit the left side of her head and chin with a metal rod. She was then taken to the school and forced to keep her head down in the mud as punishment for having resisted. Hala reported that she heard perpetrators of the massacre ordering which women to keep alive in the school and which ones to shoot. Hala also stated that she saw two young women being raped and that one had a baby whom the soldier threw into a fire; women she saw leaving the school were bleeding and those who stayed were crying and screaming.

The Myanmar security forces told Hala that if she wanted to stay alive, she should give them her valuables. After they took her gold jewelry, they ordered her to leave but she stood still in shock so they stabbed her just below her left breast with a knife that was attached to the end of a gun. Hala then ran back to her home, where she saw her dead husband and son. Her daughter was alive but bleeding, so she stayed with her until others came to help and took them to a nearby village. A local doctor cleaned and bandaged their wounds. They then set out on a 12-day walk to Bangladesh; one of Hala’s elder sons and a nephew carried her wounded daughter in a blanket through heavy rains and mud up to their thighs.

PHR Medical Evaluation

The physical findings of Hala’s examination are highly consistent with her testimony of being beaten and stabbed.

Her physical examination revealed a jagged 1 cm x 3 mm scar on the right side of her chin with a depressed groove and elevated margins that is consistent with blunt trauma from a rigid object causing crushing of the skin. Hala also has an oval shaped 2 cm x 1.5 cm hypopigmented (lighter) scar over her left breast, starting 1 cm inferior to (below) the nipple. This scar has a linear 1 cm hyperpigmented (darker) depressed groove in the middle. This breast wound is consistent with a healed laceration from a blunt knife and a crush injury of the skin. Although PHR did not conduct a full psychological assessment of Hala, she cried throughout the interview and had a depressed and anxious affect. She describes nightmares and symptoms of depression due to the loss of many family members and to being a widow in a refugee camp. These psychological symptoms are highly consistent with a diagnosis of post-traumatic stress disorder.



PHR's forensic medical examination of Hala Banu found a scar on the right side of her chin which is consistent with her testimony of having been struck on the face with a metal rod.

Photo: Physicians for Human Rights

Profile 20: Kismath Fatima, 20-year-old woman¹⁰⁸

Kismath Fatima reported that, on the day of the Chut Pyin attack, she was taken from her home to the school in the military camp area, where dozens of women were held and many were raped. After her attackers took her gold jewelry, they blindfolded her and tied up her legs. They also tied her hands behind her back and she was forced to lie down with her face up. Kismath told PHR that she was raped numerous times but did not know the exact number of men who assaulted her because she was blindfolded. Her attackers repeatedly groped her body and, whenever she tried to move away, they slapped and kicked her face. They also beat her in the head, face, shoulders, and torso with a gun. One man stabbed her right forearm with a knife attached to the end of a gun.

Kismath estimates, based on the sunlight when she was finally let go, that the attackers held her in the school for roughly four hours. She and five other women ran to the forest naked, even though they could barely run or walk due to pain. They hid there for hours until family members came and carried them to a neighboring village. After seeing a doctor in this village, Kismath walked five days to Bangladesh. She described heavy bleeding and bruising in the hours and days after the gang rape. Six months later, she still reported persistent dull abdominal pain and nightmares. Her menstrual cycle also was still not regular.

PHR Medical Evaluation

The findings of Kismath's examination are highly consistent with her testimony.

Kismath's abdominal physical exam findings are consistent with having prior pelvic trauma, which is consistent with being raped multiple times for multiple hours, as she described. Six months after the gang rape, Kismath still has chronic abdominal pain. She also has a well-healed 1.5 cm x 0.8 cm hyperpigmented (darker) linear scar on her right forearm 6 cm above the wrist. The scar has jagged borders with a hypopigmented (lighter) central line that is typical of a healed stab wound from a knife, with significant pressure on the knife causing crushing of skin tissue lateral to (to the side of) the laceration.

While PHR did not conduct a formal psychological assessment, Kismath cried throughout the interview and has a flat depressed affect. She exhibits symptoms and signs of depression and post-traumatic stress disorder consistent with her testimony.

"They damaged my life. I cannot work. I cannot take care of my family. I cannot do anything."

Abdul Roshid was shot as he ran through gunfire during the attack on Chut Pyin. He then hid by a pond, from where he witnessed people being killed and women being raped. Three men then found him; while a soldier with a gun held him down, Abdul was stepped on and kicked in the left side of the chest, torso, and leg. Eventually they left him in the field and he was found in the evening by neighbors who took him to a nearby village. There was no available doctor to see him, so Abdul used local remedies such as garlic and turmeric to treat his wounds. He remained in the village for six days and the gunshot entry wound became red and swollen with infection, draining pus and developing a foul odor. Over three days, Abdul's brother and father carried him to the Bangladesh border, where his wound was washed and he was given medication at a hospital.

PHR Medical Evaluation

Overall, the physical findings are highly consistent with Abdul's report of being shot in the left leg while fleeing and then being beaten.

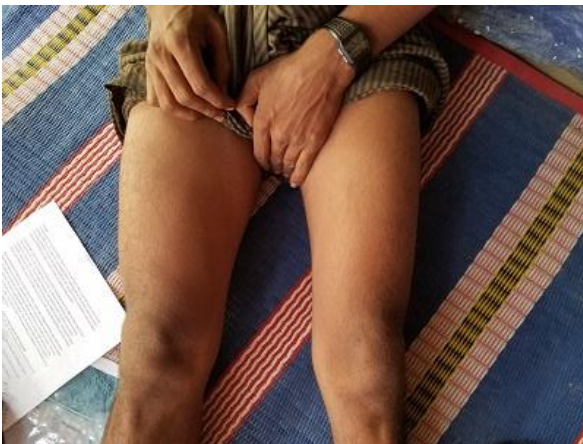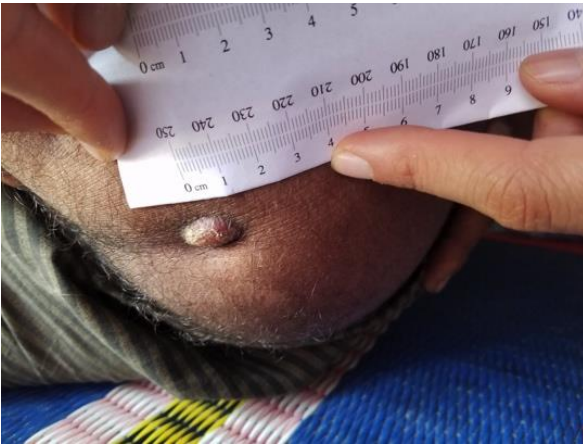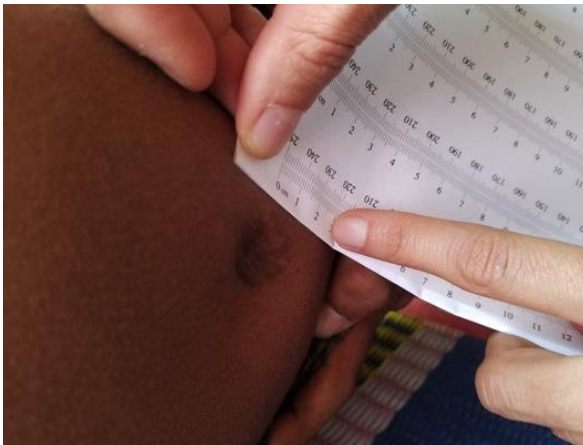His left leg examination is a textbook example of a gunshot wound with nerve destruction. A 1.5 cm circular depressed and hyperpigmented (darker) wound on the medial upper left thigh is typical of a bullet entry wound with enlargement secondary to a skin infection. A 1 cm x 0.5 cm wound with a skin protuberance on the left posterior upper thigh below the buttock represents the bullet exit wound. The bullet likely traveled through Abdul's medial thigh to the posterior area, damaging the peroneal nerve and disrupting muscles and ligaments along the way.

There also is atrophy of the calf and thigh muscles, and Abdul has a limp. On neurological exam, he has weakness of the left leg (4/5 strength in the upper leg and 0/5 strength in the ankle/foot), with a left foot drop and sensory deficits (lack of sensation) of anterior and medial aspects of the lower left leg (on the inside of the calf) typical of a peroneal nerve injury. The finding of muscle tenderness over the back is also highly consistent with his testimony of being kicked and stepped on while lying, curled up, in a defensive position. He reports left hip and back pain with tenderness to palpation on the left paraspinal muscle along the fourth and fifth lumbar region, as well as muscle tenderness over the iliac crest (hip), probably secondary to being beaten.

Although PHR did not conduct a full psychological assessment, Abdul has a poor affect and shows symptoms of depression and post-traumatic stress disorder that are highly consistent with his experience. He reports that he is married with two sons, but that he now cannot provide for his family.

PHR's forensic examination of Abdul Roshid found scars on his left leg typical of a bullet entry wound (top) and exit wound (center). He suffered nerve damage in his left leg, which is atrophied, (bottom) and he walks with a limp.

Photos: Physicians for Human Rights



Profile 22: Mohammed Aziz, 12-year-old boy¹¹⁰

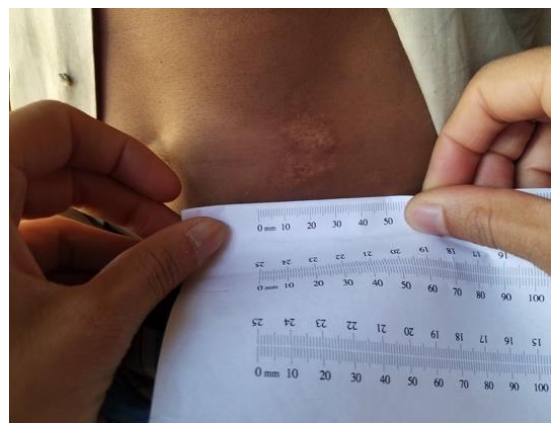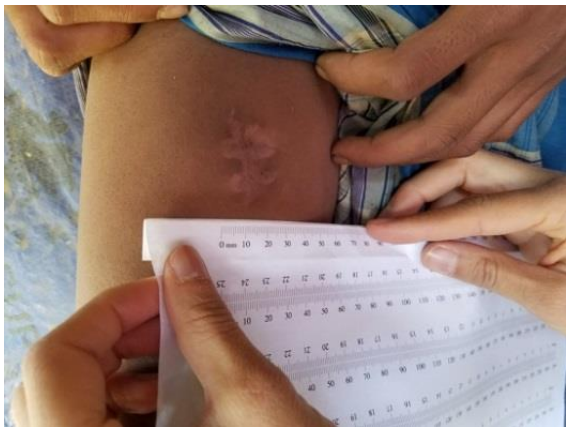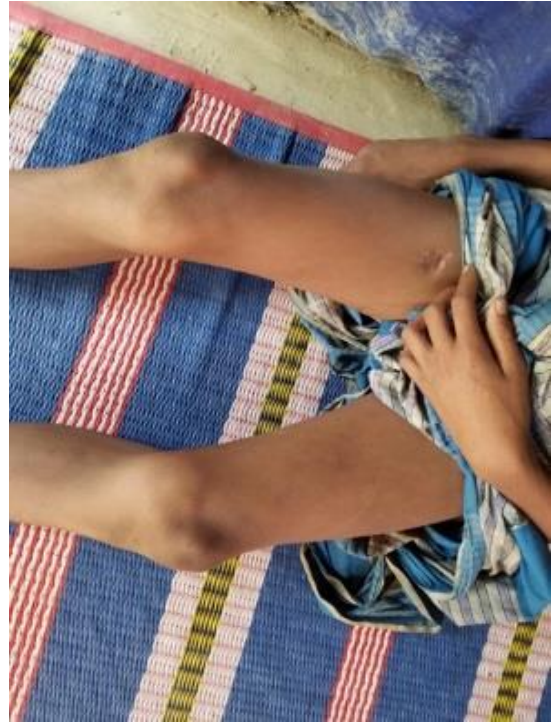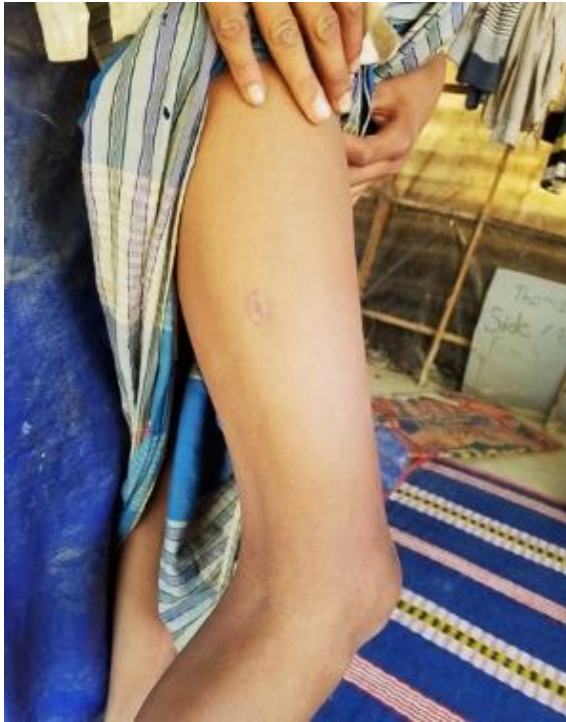Mohammed Aziz was home when Myanmar security forces shot into his house, hitting his right leg. As the attackers set his house on fire, Mohammed escaped toward the rice fields, where he witnessed attackers beat, kick, and stab injured people and then take their valuables. Mohammed saw his brother being beaten, which led the brother to lose hearing in his right ear. When the attackers approached Mohammed and his brother, the siblings pretended to be dead. Once the attackers left Chut Pyin, Mohammed's brother carried him to a nearby village, where a doctor gave him an injection and bandaged his wound with fabric. His brother then went back to Chut Pyin to find any other living family members. An uncle carried Mohammed to Bangladesh over a 13-day journey. During this time, his wound became swollen and red, and he ultimately spent two days at a hospital.

PHR Medical Evaluation

Mohammed's testimony is highly consistent with his report of suffering a gunshot wound, and suggests that a bullet traveled from his lateral (side) thigh through the leg to the medial (inner) thigh and grazed his left lower abdomen as it exited. He has a 1 cm x 1.5 cm oval shaped hypopigmented (lighter) well-healed scar on the right lateral upper leg, typical of a healed gunshot entry wound. He also has a 1.5 cm x 2 cm hypopigmented (lighter) irregular scar on the medial right thigh superior to the lateral wound, indicating that the bullet entered Mohammed's leg at an upwards-facing angle. He also has a superficial linear hypopigmented (lighter) scar over his left lower abdomen, which is co-linear with the angle of the bullet track in the thigh.

On neurological examination, Mohammed has mild tenderness to palpation over the lateral leg wound and mild weakness diffusely over his right thigh, lower leg, and foot (4.5/5 strength), but no sensory deficits. He has some atrophy of the right leg muscles, and his right leg is significantly thinner and smaller than the left leg.

Although PHR did not conduct a full psychological assessment, Mohammed shows signs of mental psychological trauma highly consistent with his testimony. Due to constant pain in the left thigh and not being able to feel much of his right leg, he reports that he cannot play with other children or sit down for a long time at school. He has difficulty with walking, especially up or down stairs or hills.



PHR's forensic medical examination of Mohammed Aziz found injuries consistent with the 12-year-old's testimony of having been struck by a bullet on the outer part of his right thigh (top left). A larger scar on the inside of his thigh is visible in the top right and lower left images and is consistent with an exit wound of a bullet traveling in an upward trajectory. The bottom right image, of a scar on Mohammed's stomach, is consistent with a wound caused by the bullet grazing Mohammed's stomach after it exited from his leg.

Photos: Physicians for Human Rights

Endnotes

Cover quote from an interview with Mohammed Foyas, Thangkali Camp, Bangladesh, March 12, 2018.

1 UN Office of the High Commissioner for Human Rights (OHCHR), *Report of OHCHR Mission to Bangladesh: Interviews with Rohingya fleeing from Myanmar since 9 October 2016*, (3 February, 2017):

<https://www.ohchr.org/Documents/Countries/MM/FlashReport3Feb2017.pdf> (p. 7-13).

2 "UN Security Council: Refer Myanmar to the International Criminal Court," news release, May 8, 2018:

<http://www.fortifyrights.org/publication-20180508.html>.

3 The UN Refugee Agency, "Rohingya Emergency," UNHCR Emergency Briefing: <http://www.unhcr.org/en-us/rohingya-emergency.html>.

4 Param-Preet Singh, "Myanmar's Proposed Rakhine Commission Latest Sham," Human Rights Watch (June 3, 2018):

<https://www.hrw.org/news/2018/06/03/myanmars-proposed-rakhine-commission-latest-sham>.

5 United Nations Human Rights Office of the High Commissioner, "End of mission Statement by Special Rapporteur on the situation of human rights in Myanmar," Yanghee Lee, Seoul (February 1, 2018):

<https://www.ohchr.org/EN/NewsEvents/Pages/DisplayNews.aspx?NewsID=22619&LangID=E>.

6 Ben Westcott, "Myanmar's Military Clears Itself Over Reported Rohingya Atrocities," *CNN*:

<https://www.cnn.com/2017/11/13/asia/myanmar-military-rohingya/index.html>.

7 Edith M. Lederer, "4 Rights Group Urge UN Security Council to Refer Myanmar to ICC," Associated Press, May 8, 2018:

<https://www.apnews.com/14ae6dec5f2479cb60b3b12f69670b0>.

8 "ICC Gives Myanmar Deadline over case jurisdiction," *Al Jazeera*, (June 23, 2018): <https://www.aljazeera.com/news/2018/06/icc-myanmar-deadline-rohingya-case-jurisdiction-180623072344220.html>.

9 "Myanmar's Proposed Rakhine Commission Latest Sham"

10 Shoon Naing, Thu Thu Aung, "Seven Myanmar soldiers sentenced to 10 years for Rohingya massacre," Reuters, April 2018:

<https://www.reuters.com/article/us-myanmar-rohingya-military/seven-myanmar-soldiers-sentenced-to-10-years-for-rohingya-massacre-idUSKBN1HH2ZS>.

11 *Myanmar: A New Muslim Insurgency in Rakhine State*, report no. 283, South East Asia (International Crisis Group, 2016):

<https://www.crisisgroup.org/asia/south-east-asia/myanmar/283-myanmar-new-muslim-insurgency-rakhine-state>.

12 World Medical Association, "World Medical Association Declaration of Helsinki: Ethical Principles for Medical Research Involving Human Subjects," *JAMA*. 2013; 310(20):2191-2194. doi:10.1001/jama.2013.281053: <https://www.wma.net/policies-post/wma-declaration-of-helsinki-ethical-principles-for-medical-research-involving-human-subjects/>.

13 The PHR clinical team used an adapted version of the "The Manual on Effective Investigation and Documentation of Torture and Other Cruel, Inhuman or Degrading Treatment or Punishment." Known as the Istanbul Protocol, this document is available at <http://physiciansforhumanrights.org/issues/torture/international-torture/istanbul-protocol.html>.

14 "Patterns of Anti-Muslim Violence in Burma: A Call for Accountability and Prevention," Physicians for Human Rights (New York, NY), August 2013: https://s3.amazonaws.com/PHR_Reports/Burma-Violence-Report-August-2013.pdf.

15 "Myanmar/Burma - Muslims and Rohingya," in World Directory of Minorities and Indigenous Peoples (Minority Rights Group International): <http://minorityrights.org/minorities/muslims-and-rohingya/>.

16 Ibid.

17 Adam Taylor, "The Battle over the word 'Rohingya'," *The Washington Post*, (Washington, DC), April 29, 2016:

https://www.washingtonpost.com/news/worldviews/wp/2016/04/29/the-battle-over-the-word-rohingya/?noredirect=on&utm_term=.6ee72627601c.

18 "Burma: End Abuses Against Rohingya," *Human Rights Watch* (May 25, 2009): <https://www.hrw.org/news/2009/05/25/burma-end-abuses-against-rohingya>.

19 "Myanmar/Burma - Muslims and Rohingya."

20 Benjamin Zawacki, "Defining Myanmar's 'Rohingya Problem,'" Human Rights Brief 20, no. 3 (January 2013):

<http://digitalcommons.wcl.american.edu/hrbrief/vol20/iss3/2> (p. 9).

21 The UN Refugee Agency. Adrian Edwards, "One year on: Displacement in Rakhine state, Myanmar," summary of press briefing, June 7, 2013: <http://www.unhcr.org/en-us/news/briefing/2013/6/51b1af0b6/year-displacement-rakhine-state-myanmar.html>.

22 Martin Petty, "Rohingya Muslims 'persecuted' after Myanmar crackdown," *Reuters*, 2012: <https://www.reuters.com/article/us-myanmar-violence/rohingya-muslims-persecuted-after-myanmar-crackdown-report-idUSBRE87005A20120801>.

23 Aman Ullah, "Politics of Changing Colour of Cards," *The Stateless Rohingya* (February 3, 2017):

<http://www.thestateless.com/2017/03/politics-of-changing-colour-of-cards.html>.

24 Megan Specia, "The Rohingya in Myanmar: How Years of Strife Grew Into a Crisis," *The New York Times* (New York, NY), September 13, 2017: <https://www.nytimes.com/2017/09/13/world/asia/myanmar-rohingya-muslim.html>.

25 Jonah Fisher, "Myanmar's 2015 Landmark Elections Explained," *BBC News*, last modified December 3, 2015: <https://www.bbc.com/news/world-asia-33547036>.

26 Shashank Bengali, "Myanmar's long-suffering Rohingya Muslims hoped that Aung San Suu would make them full citizens. They were wrong," *Los Angeles Times* (Los Angeles, CA), April 9, 2017: <http://www.latimes.com/world/la-fg-myanmar-rohingya-2017-story.html>; "Politics of Changing Colour of Cards."

27 Wai Moe, "Dozens Believed Killed as Violence Erupts in Myanmar," *The New York Times* (New York, NY), October 10, 2016: <https://www.nytimes.com/2016/10/11/world/asia/myanmar-attack-rakhine.html>.

28 Faisal Edroos, "ARSA: Who are the Arakan Rohingya Salvation Army?," *Al Jazeera*, last modified September 13, 2017: <https://www.aljazeera.com/news/2017/09/myanmar-arakan-rohingya-salvation-army-170912060700394.html>.

29 Ibid.

30 *Report of OHCHR Mission to Bangladesh: Interviews with Rohingyas fleeing from Myanmar since 9 October 2016* (p. 37).

31 *Myanmar: A New Muslim Insurgency in Rakhine State*.

32 "Who Are the Rohingyas?," *Al Jazeera*, last modified April 18, 2018: <https://www.aljazeera.com/indepth/features/2017/08/rohingya-muslims-170831065142812.html#gone>.

33 Fiona MacGregor, "As Tragedy Unfolds in Myanmar, the People's Heroine Stokes the Flames of Hatred – Foreign Policy," *Foreign Policy*, September 2017; Specia, "The Rohingya in Myanmar: How Years of Strife Grew Into a Crisis."

34 Alal O Dulal Collective, "Burma's Muslims and the War on Terror," *The Wire*, September 2017: <https://doi.org/10.1080/10576100490275094>.

35 "Myanmar Police Claim Rohingya Torched Their Own Homes," *South China Morning Post*, September 7, 2017: <http://www.scmp.com/news/asia/south-asia/article/2110155/they-burned-their-own-houses-and-ran-away-myanmar-police-tell>; Tom Miles, "Myanmar says it would like to see 'clear evidence' of genocide," *Reuters*, 8 March 2018: <https://www.reuters.com/article/us-myanmar-rohingya-rights/myanmar-says-it-would-like-to-see-clear-evidence-of-genocide-idUSKCN1GK2JH>

36 The UN Refugee Agency, "Rohingya Emergency," UNHCR Emergency Briefing: <http://www.unhcr.org/en-us/rohingya-emergency.html?query=>.

37 Unless otherwise noted, general information on Chut Pyin included in this report was drawn from consistent information in and confirmed by multiple interviews, news sources, and other key informants interviewed by PHR.

38 Fortify Rights, "Myanmar: End Attacks in Rakhine State, Protect Civilians," (Kutupalong), September 1, 2017: <http://www.fortifyrights.org/publication-20170901.html>.

39 Amnesty International, *'We Will Destroy Everything' Military Responsibility for Crimes against Humanity in Rakhine State, Myanmar*, June 29, 2018: <https://www.amnesty.org/download/Documents/ASA1686302018ENGLISH.PDF> (p.62).

40 Interview with Anis Ullah, Thangkali Camp, Bangladesh, March 11, 2018.

41 United States Department of State, 2017 Country Reports on Human Rights Practices – Burma, April 20, 2018: <https://www.state.gov/j/drl/rls/hrrpt/2017/eap/277069.htm>.

42 Interview with Mohammed Foyas, Thangkali Camp, Bangladesh, March 12, 2018.

43 Interviews with Anis Ullah, Mohammed Foyas, and Hamid Hussaun, Thangkali Camp, Bangladesh, March 11 and 12, 2018.

44 Interviews with Mohammed Foyas, Anis Ullah, Somaia Akter, and Abdu Salam, Thangkali Camp, Bangladesh, March 11, 12, and 13, 2018.

45 Interview with Mohammed Foyas, Thangkali Camp, Bangladesh, March 12, 2018.

46 Ibid.

47 Interview with Sultan Ahmed, Thangkali Camp, Bangladesh, February 24, 2018.

48 Interview with Anis Ullah, Thangkali Camp, Bangladesh, March 11, 2018.

49 Zeid Ra'ad Al-Hussein, *UN High Commissioner for Human Rights Zeid Ra'ad Al Hussein highlights human rights concerns around the world in an address to the 36th session of the Human Rights Council in Geneva, 11 September 2017*, address, September 11, 2017, ohchr.org, last modified September 11, 2017: <https://www.ohchr.org/EN/NewsEvents/Pages/DisplayNews.aspx?NewsID=22044&LangID=E>.

50 Amnesty International, *Myanmar: Crimes against humanity terrorize and drive Rohingya out* (October 18, 2017): <https://www.amnesty.org/en/latest/news/2017/10/myanmar-new-evidence-of-systematic-campaign-to-terrorize-and-drive-rohingya-out/>; Human Rights Watch, *Burma: Events of 2017* (2018): <https://www.hrw.org/world-report/2018/country-chapters/burma>; Fortify Rights, "They Tried to Kill Us All": Atrocity Crimes Against Rohingya Muslims in Rakhine State (November 2017): http://www.fortifyrights.org/downloads/THEY_TRIED_TO_KILL_US_ALL_Atrocity_Crimes_against_Rohingya_Muslims_Nov_2017.pdf (p. 13); UN Human Rights Council, Report of the Special Rapporteur on the situation of human rights in Myanmar, 23 March 2018,

A/HRC/37/70, p. 14-15; Amnesty International, *My World is Finished: Rohingya Targeted in Crimes against Humanity*, report (18 October 2017): <https://www.amnesty.org/download/Documents/ASA1672882017ENGLISH.PDF> (p. 43, 47).

51 UN General Assembly, *Rome Statute of the International Criminal Court* (last amended 2010), 17 July 1998, ISBN No. 92-9227-227-6, available at: <http://www.refworld.org/docid/3ae6b3a84.html>.

52 International Criminal Court (ICC), *Elements of Crimes*, 2011, ISBN no. 92-9227-232-2, available at <https://www.icc-cpi.int/NR/rdonlyres/336923D8-A6AD-40EC-AD7B-45BF9DE73D56/0/ElementsOfCrimesEng.pdf> (p. 6).

53 "ICC Gives Myanmar Deadline over case jurisdiction."

54 "ICC Gives Myanmar deadline over Rohingya case jurisdiction," *Reuters* (June 21, 2018): <https://www.reuters.com/article/us-myanmar-rohingya-icc/icc-gives-myanmar-deadline-over-rohingya-case-jurisdiction-idUSKBN1JH24M>.

55 UN, *The Core International Human Rights Treaties* (ISBN 92-1-154166-2): <http://www.ohchr.org/Documents/Publications/CoreTreatiesen.pdf> (p. 3, 13, 26, 100, 111, 113).

56 UN General Assembly, *International Covenant on Civil and Political Rights*, 16 December 1966, United Nations, Treaty Series, vol. 999, p. 171, available at: <https://www.ohchr.org/en/professionalinterest/pages/ccpr.aspx>.

57 UN General Assembly, *International Covenant on Civil and Political Rights*, 16 December 1966, United Nations, Treaty Series, vol. 999, p. 171, available at: <https://www.ohchr.org/en/professionalinterest/pages/ccpr.aspx>.

58 UN General Assembly, *Convention on the Elimination of All Forms of Discrimination Against Women*, 18 December 1979, United Nations, Treaty Series, vol. 1249, available at: <https://www.ohchr.org/EN/ProfessionalInterest/Pages/CEDAW.aspx>.

59 UN General Assembly, *Convention on the Rights of Persons with Disabilities* : resolution / adopted by the General Assembly, 24 January 2007, A/RES/61/106, available at: <https://www.ohchr.org/EN/HRBodies/CRPD/Pages/ConventionRightsPersonsWithDisabilities.aspx>.

60 UN General Assembly, *Universal Declaration of Human Rights*, 10 December 1948, 217 A (III), available at: <http://www.un.org/en/universal-declaration-human-rights/>.

61 Interview with Anis Ullah, Thangkali Refugee Camp, Bangladesh, March 12, 2018; Frontline, "Myanmar's Killing Fields," episode 18, PBS, May 8, 2018, produced by Evan Williams and Dan Edge: <https://www.pbs.org/wgbh/frontline/film/myanmars-killing-fields>.

62 Bernat Armangue, "Myanmar Military Says Death Toll in Clashes Almost 400," *Associated Press*, September 2, 2017: <https://www.apnews.com/14ae6decd5f2479cb60b3b12f69670b0>.

63 UN General Assembly, *Convention Against Torture and Other Cruel, Inhuman or Degrading Treatment or Punishment*, 10 December 1984, United Nations, Treaty Series, vol. 1465, available at <https://www.ohchr.org/EN/ProfessionalInterest/Pages/CAT.aspx>.

64 Manfred Nowak and Elizabeth McArthur, "The distinction between torture and cruel, inhuman or degrading treatment," *Torture*, Vol. 16, No. 3, 2006, pp. 147–151. "Lawful purposes" include effecting a lawful arrest, preventing the escape of a person lawfully detained, self-defense or defense of others from unlawful violence, and action lawfully taken to quell a riot or insurrection.

65 *Torture in International Law: a Guide to Jurisprudence*, APT (Geneva, SUI) and CEJIL (Washington, D.C.) 2008: https://www.apr.ch/content/files_res/jurisprudenceguide.pdf (page 2).

66 General Recommendation 19, (11th session, 1992), paragraph 7, The Committee on the Elimination of All Forms of Discrimination against Women (CEDAW): "Gender-based violence, which impairs or nullifies the enjoyment by women of human rights and fundamental freedoms under general international law or under human rights conventions, is discrimination within the meaning of article 1 of the Convention. These rights and freedoms include: (a) The right to life; (b) The right not to be subject to torture or to cruel, inhuman or degrading treatment or punishment; (c) The right to equal protection according to humanitarian norms in time of international or internal armed conflict; (d) The right to liberty and security of person; (e) The right to equal protection under the law; (f) The right to equality in the family; (g) The right to the highest standard attainable of physical and mental health; (h) The right to just and favourable conditions of work."

67 Asia Watch, *Burma: Rape, Forced Labor, and Religious Persecution in Northern Arakan* (New York: Human Rights Watch, 1992): <https://es.scribd.com/document/56585572/Burma-Rape-Forced-Labor-Religious-Persecution-In-Northern-Arakan> (p. 8).

68 Interview with Sultan Ahmed, Thangkali Camp, Bangladesh, February 24, 2018.

69 Interview with Anis Ullah, Thangkali Camp, Bangladesh, March 11, 2018.

70 Antoni Slodkowski, "Myanmar rejects reports army killed Rohingya fleeing Rakhine conflict," *Reuters* (November 18, 2016): <https://www.reuters.com/article/us-myanmar-rohingya-idUSKBN13D255>.

71 International Criminal Court (ICC), *Elements of Crimes*, 2011, ISBN no. 92-9227-232-2, available at <https://www.icc-cpi.int/NR/rdonlyres/336923D8-A6AD-40EC-AD7B-45BF9DE73D56/0/ElementsOfCrimesEng.pdf> (p. 6).

72 Interview with Mohammed Foyas, Thangkali Camp, Bangladesh, March 12, 2018.

73 Ibid.

74 Interview with Hamid Hussaun, Mohammed Ismail, and Abdu Salam, Thangkali Camp, Bangladesh, March 12 and 13, 2018.

75 Reuters, *GRAPHIC-A Visual That Shows Just How Many Rohingya Villages Have Been Burned*, (2018): <http://news.trust.org/item/20180101040551-ihq2m>.

-
- 76 UN General Assembly, *International Covenant on Economic, Social and Cultural Rights*, 16 December 1966, United Nations, Treaty Series, vol. 993, p. 3, available at: <https://www.ohchr.org/EN/ProfessionalInterest/Pages/CESCR.aspx>.
- 77 CESCR General Comment No. 14: The Right to the Highest Attainable Standard of Health (Art. 12): <http://www.refworld.org/pdfid/4538838d0.pdf>.
- 78 "Myanmar Says 400 Killed, 2,600 Houses Burned in Rakhine, Blames Insurgents," *Daily Sabah* (Istanbul), September 2, 2017, Asia Pacific: <https://www.dailysabah.com/asia/2017/09/02/myanmar-says-400-killed-2600-houses-burned-in-rakhine-blames-insurgents>.
- 79 Ben Westcott, "Myanmar's Military Clears Itself Over Reported Rohingya Atrocities," *CNN*: <https://www.cnn.com/2017/11/13/asia/myanmar-military-rohingya/index.html>.
- 80 Shoon Naing, Thu Thu Aung, "Seven Myanmar soldiers sentenced to 10 years for Rohingya massacre," Reuters, April 2018: <https://www.reuters.com/article/us-myanmar-rohingya-military/seven-myanmar-soldiers-sentenced-to-10-years-for-rohingya-massacre-idUSKBN1HH2ZS>.
- 81 *Report of OHCHR mission to Bangladesh: Interviews with Rohingyas fleeing from Myanmar since 9 October 2016* (p. 7).
- 82 Ibid, (p.39).
- 83 Ibid, (p. 31).
- 84 Jon Emont and Niharika Mandhana, "We'll Turn Your Villages into Soil': Survivors Recount One of Myanmar's Biggest Massacres," *Wall Street Journal* (May 11, 2018): <https://www.wsj.com/articles/burn-the-houses-rohingya-survivors-recount-the-day-soldiers-killed-hundreds-1526048545>; Amnesty International, Myanmar: Crimes against humanity terrorize and drive Rohingya out (October 18, 2017): <https://www.amnesty.org/en/latest/news/2017/10/myanmar-new-evidence-of-systematic-campaign-to-terrorize-and-drive-rohingya-out/>.
- 85 "Myanmar's Proposed Rakhine Commission Latest Sham."
- 86 Ibid.
- 87 United Nations Human Rights Office of the High Commissioner, "End of mission Statement by Special Rapporteur on the situation of human rights in Myanmar," Yanghee Lee, Seoul (February 1, 2018): <https://www.ohchr.org/EN/NewsEvents/Pages/DisplayNews.aspx?NewsID=22619&LangID=E>.
- 88 "ICC Gives Myanmar Deadline over case jurisdiction."
- 89 Interview with Laila Baegum, Thangkali Camp, Bangladesh, February 24, 2018.
- 90 Interview with Shofiqul Islam, Thangkali Camp, Bangladesh, February 24, 2018.
- 91 Interview with Anwar Sadak, Thangkali Camp, Bangladesh, February 24, 2018.
- 92 Interview with Rabia Basri, Thangkali Camp, Bangladesh, February 24, 2018.
- 93 Interview with Mohammed Isaq, Thangkali Camp, Bangladesh, February 24, 2018.
- 94 Interview with Nur Asha, Thangkali Camp, Bangladesh, February 26, 2018.
- 95 Interview with Somaiya Akter, Thangkali Camp, Bangladesh, February 24, 2018.
- 96 Interview with Sayed Alom, Thangkali Camp, Bangladesh, February 24, 2018.
- 97 Interview with Sultan Ahmed, Thangkali Camp, Bangladesh, February 24, 2018.
- 98 Interview with Rahama Bi Bi, Thangkali Camp, Bangladesh, February 25, 2018.
- 99 Interview with Rahamed Ullah, Thangkali Camp, Bangladesh, February 25, 2018.
- 100 Interview with Jahan Ara, Thangkali Camp, Bangladesh, February 26, 2018.
- 101 Interview with Ayaesha Siddiq, Thangkali Camp, Bangladesh, February 26, 2018.
- 102 Interview with Abaeda Khatu, Thangkali Camp, Bangladesh, February 26, 2018.
- 103 Interview with Anayath Korim, Thangkali Camp, Bangladesh, February 27, 2018.
- 104 Interview with Mohammed Yusuf, Thangkali Camp, Bangladesh, February 27, 2018.
- 105 Interview with Mohammed Yasin, Thangkali Camp, Bangladesh, February 27, 2018.
- 106 Interview with Umma Salama, Thangkali Camp, Bangladesh, February 26, 2018.
- 107 Interview with Hala Banu, Thangkali Camp, Bangladesh, March 10, 2018.
- 108 Interview with Kismath Fatima, Thangkali Camp, Bangladesh, March 11, 2018.
- 109 Interview with Abdul Roshid, Thangkali Camp, Bangladesh, March 11, 2018.
- 110 Interview with Mohammed Aziz, Thangkali Camp, Bangladesh, March 12, 2018.



**Physicians for
Human Rights**

phr.org

For more than 30 years, Physicians for Human Rights (PHR) has used science and the uniquely credible voices of medical professionals to document and call attention to severe human rights violations around the world. A Nobel Peace Prize co-laureate, PHR uses its investigations and expertise to advocate for persecuted health workers and facilities under attack, prevent torture, document mass atrocities, and hold those who violate human rights accountable.

Through evidence,
change is possible.



Nobel Peace Prize
Co-laureate